

## Case Report

# Massive *Trichuris trichiura* Infection as a Cause of Chronic Bloody Diarrhea in a Child

by Daniel R. Diniz-Santos,<sup>a</sup> Jamile Jambeiro,<sup>a</sup> Ramiro R. Mascarenhas,<sup>b</sup> and Luciana R. Silva<sup>a</sup>

<sup>a</sup>*Pediatric Gastroenterology and Hepatology Division, Professor Hosannah de Oliveira Pediatric Center, Federal University of Bahia, Salvador, Brazil*

<sup>b</sup>*Digestive Endoscopy Division, Professor Edgard Santos University Hospital, Federal University of Bahia, Salvador, Brazil*

### Summary

The differential diagnosis of chronic diarrhea is extensive and requires the investigation of several diseases, such as celiac disease, inflammatory bowel disease and irritable bowel syndrome. A few patients infected by *Trichuris trichiura* may present a chronic dysentery-like syndrome in the context of a massive infestation of the colon leading to anemia and growth retardation, but the rarity of that finding demands a high level of suspicion. Herein we report the case of an 8-year-old boy from the rural zone who had suffered diarrhea without blood or mucus for 4 years and was taken to our Service because his mother had noticed the presence of blood on the feces on the 3 previous months. The diagnosis of a massive *Trichuris trichiura* infestation as the cause of the process was only reached by colonoscopy. We stress that *Trichuris trichiura* infection can mimic other forms of inflammatory bowel disease and lead to physical growth retardation and that prolonged regimens of albendazole may be required to the effective treatment of massive infestations.

### Introduction

Chronic diarrhea is a common complaint in adults and children seeking care in gastroenterology services worldwide. The differential diagnosis is broad and encompasses several groups of diseases, which may be infectious, immune-mediated, functional, oncologic, genetic or drug-induced. Chronic diarrhea may also be a feature of an extra-intestinal disease, e.g. diabetes mellitus, systemic lupus, renal failure and neuroendocrin tumors.

In children, the commonest causes have shifted away from infectious diseases not only because of the improvements on hygiene conditions but also because of the growing awareness and ability to diagnose irritable bowel syndrome (IBS), celiac disease and inflammatory bowel disease (i.e. Crohn's disease and ulcerative colitis).

### Case report

An 8-year-old boy was taken to our Service to investigate a 3-month long history of a dysentery-like

diarrhea. He had been presenting diarrhea without blood or mucus on the stools over the preceding 4 years and denied associated symptoms such as abdominal tenderness, vomiting and fever. At physical examination, the patient had low stature and weight for his age, hypochromic mucosae and an enlarged liver (5 cm below xyphoid and 4 cm below right costal margin). Rectal palpation was normal. Laboratory investigation revealed anemia (hemoglobin = 7.4 mg/dl) and eosinophilia ( $1.15 \times 10^9/l$ ), while stool analysis detected the presence of eggs of *Trichuris trichiura* and *Schistosoma mansoni*, but it was negative for the presence of *Entamoeba histolytica*. Fecal culture yielded no bacterial growth.

A colonoscopy was performed to evaluate the possibility of inflammatory bowel disease and its findings are presented in Fig. 1, where a massive population of *T. trichiura* can be seen on the colon, and in Fig. 2, which shows a close view of the worm, allowing morphological confirmation of the diagnosis.

Therapy was started with oxamniquine (20 mg/kg/d in two doses) for schistosomiasis and albendazole (400 mg/d for 3 days) for trichuriasis, but no improvement on the diarrhea or on the bleeding was observed during one week of observation. Then, albendazole was restarted at a regimen of 400 mg/d

---

Correspondence: Daniel R. Diniz-Santos, Av. Princesa Isabel, 549, apt. 11, Barra Avenida, Salvador, Bahia, CEP: 40130-030, Brazil.  
E-mail <danieldiniz82@ig.com.br>.

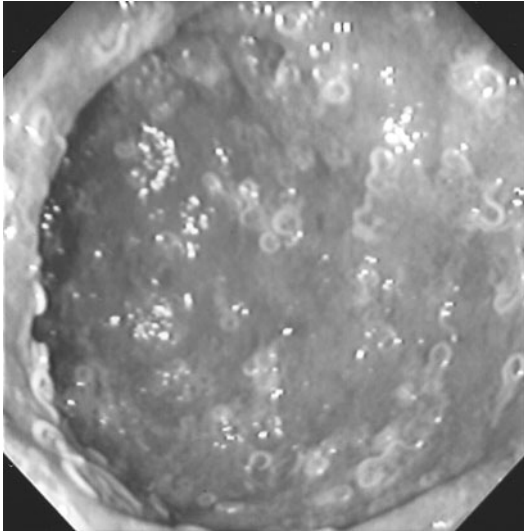


FIG. 1. Colonoscopic view of the colon, where a massive infestation of *Trichuris trichiura* is noticed.

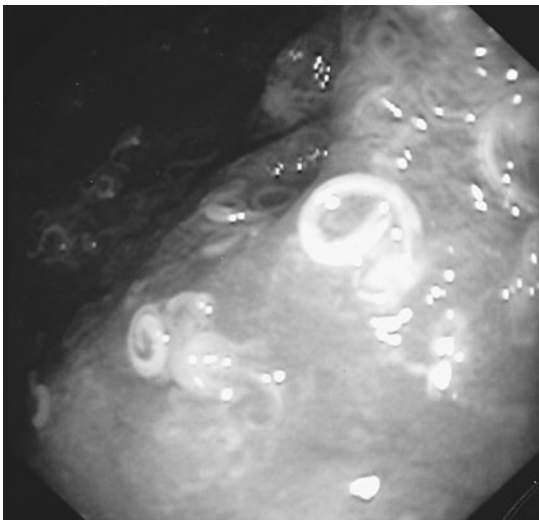


FIG. 2. Close colonoscopic view of one worm infesting the colon.

for 5 days, after which the patient recovered totally and was discharged from hospital. Currently, the patient remains free of symptoms, has gained weight and his stature is on the rise.

### Discussion

As the differential diagnosis of chronic diarrhea is very broad, an extensive and detailed history should be taken because simple information, such as the pattern of diarrhea and the appearance of stools,

might provide useful clues about the cause of the process.

We reported the case of an 8-year-old boy who presented chronic diarrhea since he was 4-year-old and was taken to our service because he had started to present blood on the stools 3 months earlier. Inflammatory bowel disease was suspected on clinical grounds and the confirmation of the diagnosis was sought by colonoscopy. Even though irritable bowel syndrome and celiac disease are important causes of chronic diarrhea in children, they had been virtually excluded from the differential diagnosis because of the presence of blood on the feces. However, it was essential to consider that the patient could have had one of those diseases and had become infected by an invasive enteropathogen like *Entamoeba histolytica*, *Shigella*, *Salmonella* or *Yersinia* even though he did not present any of the typical signs of invasive diarrhea, such as fever, abdominal pain, tenesmus and neutrophilia. Moreover, septicemic enterobacteriosis could also be considered, even though prolonged fever is one of its most prominent hallmarks. Those possibilities could only be excluded by stool analysis and culture, which did not demonstrate the presence of trophozoites or cysts of *E. histolytica* and yielded no bacterial growth. Other diseases to be considered on differential diagnosis were juvenile polyposis, intestinal tuberculosis, vascular malformations and colonic neoplasms.

The result of the colonoscopy was somewhat surprising due to its rarity. Even though trichuriasis is one of the commonest soil-transmitted helminthiases worldwide, most children affected are asymptomatic and harbor only small numbers of worms. In massive infections, patients may present a *Trichuris trichiura* dysentery syndrome consisting of abdominal pain, tenesmus and bloody diarrhea with mucus.<sup>1-3</sup> Such massive and chronic infestations are often associated with rectal prolapse too. We consider that our patient had a chronic *T. trichiura* infection whose sole manifestation was diarrhea without visible blood on the feces, but that diarrheal picture caused severe anemia and growth retardation. The change in the pattern of stools was more important because it served as a motivation for the mother to search medical help and was considered a simple progression of the disease.

Albendazole in a single dose of 400 mg is usually effective for the treatment of most helminthic infections and has replaced mebendazole because of its simple posology, which yields high compliance rates. Mebendazole in its standard regimen (100 mg twice a day for 3 days) is effective and safe for the treatment of trichuriasis, giving a cure rate of 70 per cent.<sup>4</sup> Albendazole, however, provides very lower success rates on its standard single dose regimen, but extending the treatment for three days raises the cure rates to 80 per cent.<sup>5-7</sup> Recently, it has

been demonstrated that the efficacy of albendazole for the treatment of trichuriasis depends on the total dose given, with a clear advantage of 5- and 7-day regimens for the treatment of heavy infections.<sup>8</sup> Indeed, our patient required a 5-day regimen to improve.

We stress that *Trichuris trichiura* infection can mimic other forms of inflammatory bowel disease and lead to physical growth retardation and that prolonged regimens of albendazole may be required to the effective treatment of massive infestations.

### References

1. American Academy of Pediatrics. Trichuriasis. In: Pickering LK (ed.) Red Book: 2003 Report of the Committee on Infectious Diseases. 26th ed. Elk Grove Village, IL: American Academy Pediatrics; 2003: p. 638.
2. Jung RC, Beaver PC. Clinical observations of *Trichocephalus trichiurus* (whipworm) infestations in children. *Pediatrics* 1951; 8: 548–57.
3. Gilman RH, Chong YH, Davis C, Greenberg B, Virik HK, Dixon HB. The adverse consequences of heavy *Trichuris* infection. *Trans Roy Soc Trop Med Hyg* 1983; 77: 432–38.
4. Drugs for parasitic infections. *Med Lett Drug Ther* 1998; 40: 1–8.
5. Ramalingam S, Sinniah B, Krishnan U. Albendazole, an effective single dose, broad spectrum anthelmintic drug. *Am J Trop Med Hyg.* 1983; 32: 984–89.
6. Norhayati M, Oothuman P, Azizi O, Fatmah MS. Efficacy of single dose albendazole on the prevalence and intensity of infection of soil-transmitted helminthes in Orang Asli children in Malaysia. *Southeast Asian J Trop Med Public Health* 1997; 28: 563–69.
7. Hall A, Nahar Q. Albendazole and infections with *Ascaris lumbricoides* and *Trichuris trichiura* in children in Bangladesh. *Trans Roy Soc Trop Med Hyg.* 1994; 88: 110–12.
8. Sirivichayakul C, Pojjaroen-Anant C, Wisetsing P, Praevanit R, Chanthavanich P, Limkittikul K. The effectiveness of 3, 5 or 7 days of albendazole for the treatment of *Trichuris trichiura* infection. *Ann Trop Med Parasitol* 2003; 8: 847–53.