

Does botulinum toxin injection in parotid glands interfere with the swallowing dynamics of Parkinson's disease patients?

Ana Caline Nóbrega, Bernardo Rodrigues, Ailton Melo*

Division of Neurology and Epidemiology - Federal University of Bahia, Brazil

ARTICLE INFO

Article history:

Received 19 August 2008

Received in revised form 11 December 2008

Accepted 19 December 2008

Keywords:

Parkinson's disease
Dysphagia
Swallowing disorders
Silent aspiration
Sialorrhea
Botulinum toxin

ABSTRACT

Background: During recent years, sialorrhea in Parkinson's disease (PD) has been treated with botulinum toxin type A (BT-A); however, there are no data describing its effects on swallowing dynamics in this group of patients.

Objective: To investigate whether injection of BT-A into the parotid glands interferes with the oropharyngeal swallowing dynamics of patients with Parkinson's disease.

Methods: Sixteen patients with diurnal sialorrhea were selected and evaluated during the "on" period by a standardized questionnaire and swallowing videofluoroscopy before and 30 days after ultrasound-guided BT-A injection into the parotid glands.

Results: A decrease in sialorrhea was observed in all studied patients. Silent laryngeal penetration was observed in three patients, and silent aspiration was observed in two of them. There were no changes in swallowing dynamics when comparing patients before and after BT-A parotid injection ($p = 1$), suggesting similar levels of dysphagia in the two measurements.

Conclusion: BT-A injection into parotid glands does not interfere with the oropharyngeal swallowing dynamics of PD patients.

© 2009 Published by Elsevier B.V.

1. Introduction

Sialorrhea is a frequent complaint of patients with neurological diseases such as amyotrophic lateral sclerosis, cerebral palsy, and Parkinson's disease [1]. This condition lowers patients' self-esteem, leads to social problems, interferes with oral functions and hygiene, and is a risk factor for bronchial aspirations [2]. Previous study verified that silent laryngeal penetration and silent aspiration is associated to more severe sialorrhea in PD patients [3].

Treatments for sialorrhea include anticholinergic drugs, radiation, and surgery, which often result in undesired side effects [2,4]. Since 1997, botulinum toxin type A (BT-A) has been used to treat sialorrhea resulting from neurological diseases [5], and its effectiveness is well-established [6]. In PD patients the production of saliva is reduced when compared with age-matched controls [7] and sialorrhea was correlated with dysphagia in this group of patients [8]. These observations increased concerns about the risk of BT-A diffusion to adjacent muscles and the consequences of saliva reduction on swallowing function. In the present study, we evaluated the

oropharyngeal swallowing dynamics of PD patients treated with BT-A injection into the parotid glands.

2. Methods

This study was approved by the Federal University of Bahia's Ethics Committee, and all subjects provided written consent to participate. Diagnosis of Parkinson's disease is based on the presence of bradykinesia associated with at least one of the following symptoms: muscular stiffness, 4–6 Hz resting tremors, or postural instability. Patients were assessed by a drooling score scale (from 2: no sialorrhea to 9: worst drooling). This scale sums the scores for severity and frequency of drooling according to established rating scales [9]. Patients with a drooling score equal to or greater than five were included. Exclusion criteria were dementia or severe depression, previous stroke, repeated head injuries, encephalitis, previous treatment with neuroleptics within one year prior to the onset of symptoms, pyramidal or cerebellar symptoms, early autonomic involvement, supranuclear gaze palsy, and previous treatment for drooling or use of anticholinergic drugs.

All patients answered a questionnaire concerning feeding complaints, and were subjected to a swallowing function assessment using the modified barium swallowing procedure with videofluoroscopy. In the right lateral position, patients were asked to swallow 5, 10, and 20 ml of a barium suspension mixed in thin

* Corresponding author at: Division of Neurology and Epidemiology, Avenida Magalhães Neto 735/802, Pituba, Salvador, Bahia, Brazil. Tel.: +55 71 99755275; fax: +55 71 32476982.

E-mail address: asm@ufba.br (A. Melo).

and thick fluids; 5 and 10 ml of pasty barium, and half of a biscuit with barium. Patient videos were encoded, randomly labeled, and recorded in individual compact disks for standard blind analysis by three different examiners (one radiologist and two speech therapists). Based on the criteria established in the literature [10,11], oropharyngeal swallowing dynamics was assessed ranging from normal swallowing (level 07) to severe dysphagia (level 01) [12], and further classified as poor, mild, and good swallowing status [13].

Injections containing 125 U of BT-A (Dysport) were diluted (500 U/2.5 ml of saline) and delivered into two points of each parotid gland guided by ultrasound. Drooling and swallowing evaluations were repeated 30 days after BT-A injection.

Data were analyzed with the aid of the SPSS, V10 statistical package. Descriptive statistics are presented as means \pm standard deviation (S.D.). The chi-square test was used to compare proportions between groups, and the Wilcoxon test was used to investigate differences between means before and after treatment. The sample did not represent a normal distribution and the confidence interval was established at 95%.

3. Results

Sixteen patients were evaluated, including 13 men and 3 women. All patients were evaluated during the “on” phase, and all were being treated with levodopa along with entacapone and/or pramipexole. The mean age was 70.25 ± 6.25 , ranging from 58 to 81 years. The mean disease duration was 6.6 ± 4.85 years, ranging from 2 to 22 years, and the mean Hoehn and Yahr score was 2.87 ± 0.84 , ranging from 2 to 5.

Before BT-A injection, occasional cough and an oropharyngeal bolus sensation were the most frequent complaints, both of which were described by 10 patients. After BT-A injection, 6 patients reported cough, 8 reported bolus sensation, and 9 felt more comfortable and confident during meals.

After 30 days of BT-A injection, the total score of sialorrhea decreased in 15 patients ($p = 0.001$). Fourteen patients reported a decrease in the severity of sialorrhea ($p = 0.001$) and 6 described a reduction in the frequency of sialorrhea ($p = 0.035$).

In the two measurements, silent laryngeal penetration and silent aspiration were observed in three and two patients, respectively. Table 1 shows the main data from the videofluoroscopic swallowing analysis before and after BT-A injection. Outcomes demonstrated no differences between groups ($\chi^2 = 0.162$, $p = 1$).

Fig. 1 shows the swallowing status and degree of dysphagia before and after BT-A injection. There were no differences in the means of the dysphagia scores and no changes in swallowing status before and after BT-A injection ($\chi^2 = 0.159$, $p = 0.924$).

Table 1

The main findings of videofluoroscopy of luoroscopy before and after BT-A injection.

	Abnormal findings	Before BT-A		After BT-A	
		N	%	N	%
Oral phase	Poor bolus formation	15	94	14	88
	Lingual pumping action	12	75	12	75
	Preswallow spill	14	88	13	81
	Swallow hesitancy	13	81	12	75
	Poor bolus propulsion	16	100	16	100
	Residue on the tongue	16	100	16	100
	Piecemeal swallow	14	88	15	94
Pharyngeal phase	Stasis in valleculae	15	94	14	88
	Residue in posterior pharyngeal wall	12	75	12	75
	Stasis in pyriform sinuses	14	88	13	81
	Laryngeal penetration	3	19	3	19
	Aspiration	2	13	2	13

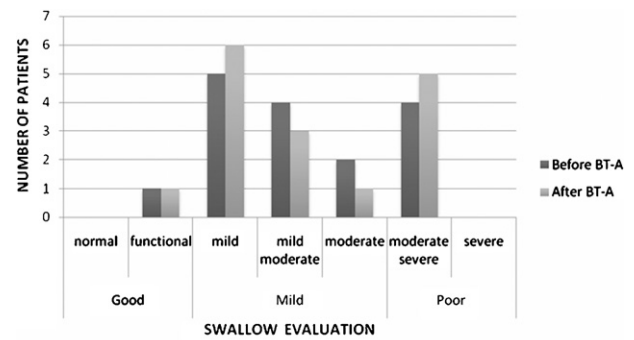


Fig. 1. Swallowing status and degree of dysphagia before and after BT-A injection.

4. Discussion

We observed that the use of BT-A in parotid glands to treat diurnal sialorrhea in PD patients does not interfere with swallowing dynamics, as observed by videofluoroscopic analysis. Although the majority of patients reported that decreased sialorrhea was associated with more comfortable and safer meals, oropharyngeal dynamics did not change before vs. after BT-A. Previously described side effects [14] were not observed, except for xerostomy in two cases.

The subjective improvement reported by patients probably reflected better social adjustment and confidence during meals, mainly in the presence of other individuals. It is important to note that the BT-A injections were only administered into parotid glands, which are responsible for the production of more than half of the aqueous saliva secreted during chewing and swallowing [15], but all patients reported previous dysphagia and consumed moist and soft meals, which require less saliva to prepare and organize the bolus while eating.

We must stress that even the decreased sialorrhea observed in the majority of patients and improved swallowing reported by some did not reduce the episodes of laryngeal penetration and/or silent aspiration, which increase the risk of respiratory infections, the main predictor of death in PD patients, 9.75-fold [16].

In this study group, difficulties associated with food bolus formation increased proportionally with larger amounts of food, while ejection difficulty and stases in the pharyngeal recesses worsened in response to increased food viscosity. This data agrees with previous authors who suggest an association between food volume and bolus organization in persons with swallowing problems [17], and between food viscosity and tongue ejection strength modulation, as well as oral cleanliness during swallowing [18].

Dysphagia due to diffusion of BT-A to muscles near parotid glands was not observed in our cases. We believe that this type of diffusion is related to technique problems, increased volume of saline or even higher doses, however further studies should be done in order to solve these questions. Previous authors suggest that guided injections are safer and more reliable, although no data with significant statistical differences related to side effects were found after comparing blind injection administration to ultrasound-guided injections of BT-A into parotid glands [19].

We concluded that BT-A injections are a safe and efficacious therapy for the treatment of sialorrhea in PD patients. When BT-A is injected only into the parotid glands, the procedure does not interfere with oropharyngeal swallowing dynamics or the frequency of food aspiration. Therefore, we suggest that further studies consider the degree of dysphagia and diet characteristics of Parkinson's disease patients with sialorrhea when selecting which salivary glands should receive the BT-A injection.

References

- [1] Potulska A, Friedman A. Controlling sialorrhoea: a review of available treatment options. *Expert Opin Pharmacother* 2005;6:1551–4.
- [2] Chou KL, Evatt M, Hinson V, Kompoliti K. Sialorrhoea in Parkinson's disease: a review. *Mov Disord* 2007;22:2306–13.
- [3] Nóbrega AC, Rodrigues B, Melo A. Silent aspiration in Parkinson's disease patients with diurnal sialorrhoea. *Clin Neurol Neurosurg* 2008;110:117–9.
- [4] Molloy L. Treatment of sialorrhoea in patients with Parkinson's disease: best current evidence. *Curr Opin Neurol* 2007;20:493–8.
- [5] Bushara KO. Sialorrhoea in amyotrophic lateral sclerosis: a hypothesis of a new treatment—botulinum toxin A injections of the parotid glands. *Med Hypotheses* 1997;48:337–9.
- [6] Truong DD, Bhidayasiri R. Evidence for the effectiveness of botulinum toxin for sialorrhoea. *J Neural Transm* 2008;115:631–5.
- [7] Proulx M, de Courval FP, Wiseman MA, Panisset M. Salivary production in Parkinson's disease. *Mov Disord* 2005;20:204–7.
- [8] Nóbrega AC, Rodrigues B, Torres AC, Scarpel RD, Neves CA, Melo A. Is drooling secondary to a swallowing disorder in patients with Parkinson's disease? *Parkinsonism Relat Disord* 2008;14:243–5.
- [9] Crysdale WS, White A. Submandibular duct relocation for drooling: a 10-year experience with 194 patients. *Otolaryngol Head Neck Surg* 1989;101:87–92.
- [10] Ali GN, Wallace KL, Schwartz R, DeCarle DJ, Zagami AS, Cook IJ. Mechanisms of oral-pharyngeal dysphagia in patients with Parkinson's disease. *Gastroenterology* 1996;110:383–92.
- [11] Nagaya M, Kachi T, Yamada T, Igata A. Videofluorographic study of swallowing in Parkinson's disease. *Dysphagia* 1998;13:95–100.
- [12] O'Neil KH, Purdy M, Falk J, Gallo L. The dysphagia outcome and severity scale. *Dysphagia* 1999;14:139–45.
- [13] Cintra AB, Vale LP, Feher O, Nishimoto IN, Kowalski LP, Angelis EC. Swallowing after chemotherapy and radiotherapy for laryngeal and hypopharyngeal carcinomas. *Rev Assoc Med Bras* 2005;51:93–9.
- [14] Jost WH. Treatment of drooling in Parkinson's disease with botulinum toxin. *Mov Disord* 1999;14:1057.
- [15] Pedersen AM, Bardow A, Jensen SB, Nauntofte B. Saliva and gastrointestinal functions of taste, mastication, swallowing and digestion. *Oral Dis* 2002;8:117–29.
- [16] Nóbrega AC, Rodrigues B, Melo A. Is silent aspiration a risk factor for respiratory infection in Parkinson's disease patients? *Parkinsonism Relat Disord* 2008;14:646–8.
- [17] Yamada EK, Siqueira KO, Xerez D, Koch HA, Costa MM. The influence of oral and pharyngeal phases on the swallowing dynamic. *Arq Gastroenterol* 2004;41:18–23.
- [18] Pouderoux P, Kahrilas PJ. Deglutitive tongue force modulation by volition, volume, and viscosity in humans. *Gastroenterology* 1995;108:1418–26.
- [19] Dogu O, Apaydin D, Sevim S, Talas DU, Aral M. Ultrasound-guided versus 'blind' intraparotid injections of botulinum toxin-A for the treatment of sialorrhoea in patients with Parkinson's disease. *Clin Neurol Neurosurg* 2004;106:93–6.