



ELSEVIER

Journal of  
**Pediatric  
urology**



# Investigation into neurogenic bladder in arthrogryposis multiplex congenita

Liubiana Arantes de Araújo<sup>a,\*</sup>,  
André Ferraz de Arruda Musegante<sup>a</sup>,  
Edjane de Oliveira Damasceno<sup>a</sup>, Ubirajara Barroso Jr<sup>b</sup>,  
Roberto Badaro<sup>c</sup>

<sup>a</sup> Center for Children's Rehabilitation of SARAH Hospital, Salvador, Brazil

<sup>b</sup> Bahiana School of Medicine, Federal University of Bahia, Brazil

<sup>c</sup> Federal University of Bahia, Brazil

Received 9 August 2012; accepted 12 December 2012

Available online 13 March 2013

## KEYWORDS

Urinary bladder;  
Neurogenic;  
Arthrogryposis;  
Urodynamic;  
Urinary tract  
infections

**Abstract** *Objective:* During the follow-up of children who had been diagnosed with arthrogryposis multiplex congenita (AMC), it was noted that some were experiencing dysfunctional voiding. Further investigation into these cases led to a diagnosis of neurogenic bladder. Few studies have investigated the relationship between AMC and neurogenic bladder, this being the first to describe the clinical characteristics of neurogenic bladder among these patients. *Methods:* A series of 26 cases were obtained from the electronic medical records of patients with AMC who were admitted to Hospital Sarah in Salvador between 1994 and 2007. The patients had all been diagnosed with neurogenic bladder through clinical symptoms, lower urinary tract exams, and urodynamic findings.

*Results:* There was urinary incontinence in 21 patients (81%), and 50% had a history of urinary tract infections. Renal function was altered in 4 patients (15%) and normal in 22 (85%). In the urodynamic study, 14 patients (64%) had detrusor overactivity and 6 (27%) had underactivity. *Conclusion:* Patients with AMC may show changes in the urinary tract, including neurogenic bladder. It is mandatory to study these symptomatic children with urinary disorders.

© 2012 Journal of Pediatric Urology Company. Published by Elsevier Ltd. All rights reserved.

\* Corresponding author. Center for Children's Rehabilitation of Salvador, SARAH Hospital, Av. Tancredo Neves, 2782, Caminho das Árvores, Salvador, Bahia 41820-900, Brazil. Tel./fax: +55 7132063333.

E-mail address: [liubiana@ig.com.br](mailto:liubiana@ig.com.br) (L. Arantes de Araújo).

## Introduction

Arthrogryposis multiplex congenita (AMC) is defined as a non-progressive congenital rigidity disorder that affects multiple joints [1,2]. There are around 150 symptoms that are associated with multiple congenital contractures. Congenital amyoplasia, the most common type of congenital arthrogryposis, usually results from impaired blood flow to the placenta and leads to the death of the embryo's marrow [3–5].

There are a few publications that establish a correlation between arthrogryposis and genitourinary changes, but not with respect to a possible association with neurogenic bladder [6]. There is a description of concomitance between arthrogryposis and the malformation of the genitourinary system, as in cryptorchidism, hypospadias, renal agenesis and lithiasis. The presence of neurogenic bladder among patients with arthrogryposis has been reported, but without a description of its characteristics [7,8].

The objective of this study was to describe the urinary symptoms and the results of urological examination of patients with neurogenic bladder and AMC.

## Materials and methods

A series of cases were analyzed in order to describe the characteristics of neurogenic bladder in patients with arthrogryposis. Between March of 1994 and January of 2007, a total of 226 patients diagnosed with AMC were admitted to Hospital Sarah of Salvador, Bahia, Brazil.

All patients with AMC who showed lower urinary tract symptoms underwent urodynamic study to investigate for neurogenic bladder, independent of their age when admitted to the hospital. The criteria for exclusion were: patients without urological data on electronic medical records, or if urodynamic study was done in another institution, but without a proper description in the electronic medical

records, and patients with other associated conditions of arthrogryposis such as spinal dysraphism, hydrocephalus, cerebral palsy, mental retardation, or paraparesis of other etiology. Fig. 1 summarizes the selection of patients.

The data were obtained by review of the electronic medical records of each patient, following a specific protocol.

The different levels of impairment were categorized with relation to the arthrogryposis classification according to Judith Hall [9]:

Type I – Predominantly limb-related disorders (amyoplasia, distal forms of arthrogryposis).

Type II – Disorders involving the limbs as well as some other body parts.

Type III – Disorders that involve the limbs as well as central nervous system (CNS) dysfunction.

The clinical manifestations investigated were: urgency, daytime incontinence, nocturnal enuresis, and the presence of a urinary tract infection as well as recurrent urinary tract infections. The exams included renal function (through both urea and creatinine tests), kidney and urinary tract ultrasounds, voiding cystourethrography, and urodynamic studies. During the urodynamic study (Medtronic Duet, Minneapolis, MN, USA), uroflowmetry was initially carried out, followed by cystometry and pressure flow studies. An anal electrode was used to record the electromyographic data of the external urethral sphincter and perineal muscles. Methods and definitions of urodynamic evaluations followed the guidelines of the International Continence Society [10]. The treatment methods were: guidance on voiding at scheduled times and intermittent bladder catheterization with or without the use of anti-cholinergic drugs.

## Statistical analysis

The data were analyzed using the statistical program SPSS v16.0 (SPSS, Chicago Inc., IL, USA). The program analyzed the mean, standard deviation and frequency of each variable.

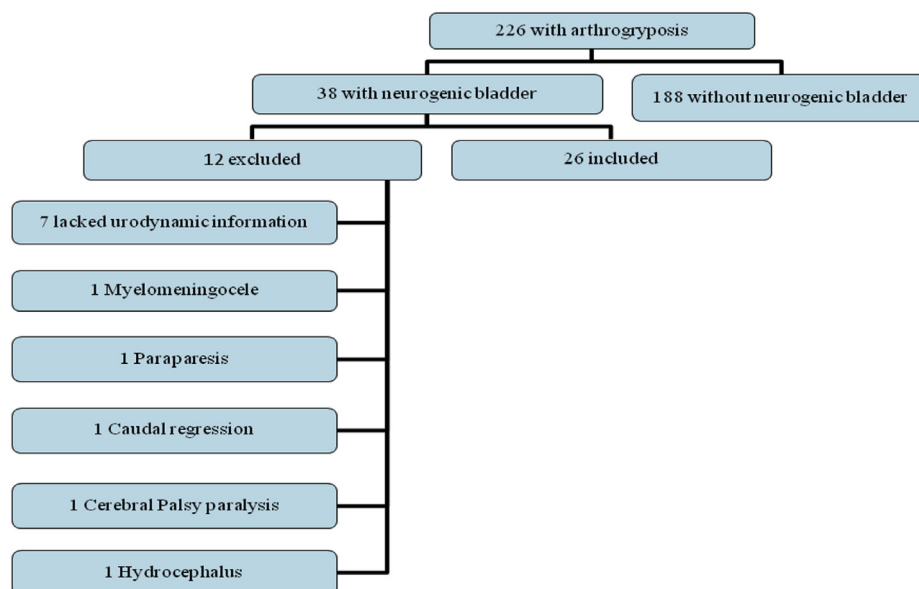


Figure 1 Patient selection process.

The Ethics Research Network of Hospital Sarah approved this investigation.

## Results

Among the 26 selected patients, 18 (69%) were male. The mean age at time of admission was 2 years, with a range between 0 and 9 years.

With respect to Hall's classification, 25 (96%) were classified as Type I, 3 with symmetrical impairment to the upper limbs and 22 with symmetrical impairment to the lower limbs. One patient's (4%) arthrogryposis was linked to multiple pterygium syndrome.

Twenty-one patients (81%) had urinary incontinence, since the parents reported diaper use at all times. Fifty percent of the patients had a previous history of urinary tract infections, recurrent in 3 cases (12%).

Pregnancy history showed that eight individuals (31%) were exposed to misoprostol with the intention to abort. The  $X^2$  test showed that there was no significant difference with regard to incontinence ( $p = 0.25$ ), urinary tract infection ( $p = 0.72$ ) and renal function ( $p = 0.74$ ) between those individuals and 15 others (69%) who were not exposed to the drug.

Electromyography was performed on 20 patients (77%) and showed a neurogenic disorder that suggested involvement of the anterior horn of the spinal cord.

The urological examination results can be found in Table 1 and Fig. 2. Among the identified changes, note the detrusor overactivity followed by detrusor underactivity.

The voiding cystourethrogram did not identify vesicoureteral reflux. Renal function was evaluated through both urea and creatinine tests, and was found to be altered in 4 patients (15%).

With regard to their treatment, 11 patients (42%) received conservative treatment, such as scheduled urination. Intermittent bladder catheterization was used in 13 patients (50%) and 9 adhered to the procedure. The anticholinergic oxybutynin was prescribed for 19 patients, 11 of whom used it regularly.

## Discussion

Neurogenic bladder can be found in patients with arthrogryposis. In infancy, it is generally a congenital disease and can result in various neurological disorders that may affect the innervations of the lower urinary tract, such as myelomeningocele and sacral agenesis [11–13].

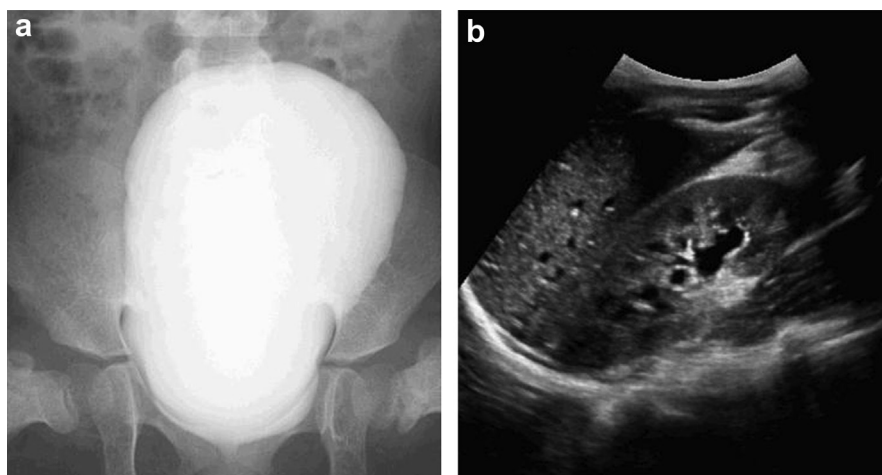
In patients with arthrogryposis, urinary tract disorders seem to have the same origin as disorders of the spinal cord [12,14,15]. The mechanism of spinal cord injury as it pertains to arthrogryposis is still uncertain. Since Type I AMC was predominant in the present study, especially amyoplasia, there is the possibility of neurogenic changes, like damage to the anterior horn cells of the spinal cord, probably due to maternal hypertension and focal hypoxia during early pregnancy, or even as a result of an intra-uterine vascular accident [4]. This hypothesis is based on reports from other studies, where the electromyography of AMC shows these neurogenic changes [16,17]. In the current study, the findings of neurogenic disorders from the electromyography of the majority of patients suggest involvement of the anterior horn of the spinal cord.

The study also showed that one third of the patients were exposed to misoprostol during pregnancy. When we examined the frequency of urinary findings of those mothers who had used misoprostol and those who had not, the results were comparable. But exposure to misoprostol compromises the vascularization of the embryo and is detrimental to the development of neuronal tissues, especially those of the spinal cord [7]. Damage to the neurons of the anterior horn of the spinal cord interferes with normal muscular development, resulting in joint changes [4], and adversely affects neuronal control of the lower urinary tract. Although suspected, this drug is not a statistically significant cause of the neurogenic bladder dysfunction in our cohort of patients.

There are few investigations regarding the association between arthrogryposis and genitourinary tract changes, and both the clinical and urological characteristics of these patients have yet to be catalogued in the literature. Goksen et al. [18] talks about the instance of neurogenic bladder in one patient with neonatal diabetes, and Quinn et al. [8] describes the presence of a hypertrophic bladder in the autopsies of patients with AMC.

**Table 1** Characteristics of urological examinations and clinical data of 26 patients with arthrogryposis multiplex congenita.

	Number	%
<i>Ultrasound</i>		
Ectasia that returns to normal after the bladder has been emptied	7	27
Ectasia/dilation that does not return to normal	2	8
Post-voiding residual	1	4
Normal	16	61
<i>Urodynamic</i>		
<b>Detrusor underactivity</b>		
Detrusor overactivity	6	23
Detrusor normal	14	54
Sphincter deficiency	6	23
Normal sphincter	2	9
Low detrusor compliance	24	91
Normal detrusor compliance	15	58
Unmeasured detrusor compliance	9	35
Normal bladder capacity	2	8
Decreased bladder capacity	6	23
20	77	
<i>Voiding cystourethrogram</i>		
Vesicoureteral reflux	0	0
Thickened bladder wall	4	15
Irregular bladder shape	3	11
Irregular bladder shape/ thickened bladder wall	13	50
Normal	6	23
<i>Symptoms</i>		
Urinary incontinence	21	81
Previous UTI	13	50
Recurrent UTI	3	12



**Figure 2** (a) Voiding cystourethrography: irregularly shaped bladder with thickened wall. (b) Kidney and urinary tract ultrasound: ectasia that returns to normal after the bladder has been emptied.

Coelho et al. [7] relates neurogenic bladder to arthrogryposis. Their sample was comprised of patients with amyoplasia, all of whom were exposed to misoprostol during gestation, which corroborates the possibility that neurogenic bladder is secondary to damage to the anterior horn cells of the marrow.

In this study, urinary incontinence was the most frequent clinical symptom, and was found in patients with neurogenic bladder stemming from other causes [12]. The urodynamic study revealed a predominance of detrusor overactivity, followed by changes in detrusor compliance.

Despite the small percentage of patients with renal function disorders within this sample, the results brought attention to the possibility of future renal function deterioration. In imaging, several changes were observed in the upper and lower urinary tracts, such as bladder wall hypertrophy and bladder distention. These findings were also present in patients with lethal congenital contractual syndrome type 2 (locus to chromosome 12q13) and those with other forms of AMC [2,19].

Also, the scarcity of publications that describe the association between these two conditions, especially prospective studies, does not permit the comparison of urological changes with the urodynamic findings. However, the knowledge that complications of neurogenic bladder can develop from arthrogryposis stresses the need for further investigation.

The study has limitations: data input was made retrospectively and taken from medical reports without a previously defined protocol to study urinary symptoms. Consequently, symptoms – e.g. those indicating neurogenic bladder – may have been underestimated.

Despite these limitations, we believe this study is valid to alert interdisciplinary teams to the high frequency of neurogenic bladder in AMC. We believe that in the follow-up of a child with arthrogryposis, the investigation of urological symptoms should be performed during the interview. If urologic symptoms are absent, only a renal ECHO and serum creatinine need be performed, because it is unlikely that additional testing would reveal further abnormalities. When the clinical history is positive, uroflowmetry and urodynamic studies should be considered. If the tests confirm neurogenic bladder, treatment should be

instituted early (anticholinergics and clean intermittent catheterization); if not, frequent follow-up is advised.

## Conclusion

Patients with AMC can present a high frequency of neurogenic bladder. In order to maintain renal health, a structured follow-up program, which includes early detection of neurogenic bladder through the investigation of urological symptoms and complementary urinary exams, including urodynamic, and subsequent treatment of these patients, is necessary.

## Conflict of interest

None.

## Financial support

The SARAH Hospital Network supported this work.

## References

- [1] Mennen U, van HA, Ezaki MB, Tonkin M, Gericke G. Arthrogryposis multiplex congenita. *J Hand Surg Br* 2005;30:468–74.
- [2] Narkis G, Ofir R, Manor E, Landau D, Elbedour K, Birk OS. Lethal congenital contractual syndrome type 2 (LCCS2) is caused by a mutation in ERBB3 (Her3), a modulator of the phosphatidylinositol-3-kinase/Akt pathway. *Am J Hum Genet* 2007;81:589–95.
- [3] Hall JG, Reed SD, Greene G. The distal arthrogryposes: delineation of new entities—review and nosologic discussion. *Am J Med Genet* 1982;11:185–239.
- [4] Hall JG, Reed SD, Driscoll EP. Part I. Amyoplasia: a common, sporadic condition with congenital contractures. *Am J Med Genet* 1983;15:571–90.
- [5] Herva R, Conradi NG, Kalimo H, Leisti J, Sourander P. A syndrome of multiple congenital contractures: neuropathological analysis on five fetal cases. *Am J Med Genet* 1988;29:67–76.
- [6] Gill IB, Gupta NP, Oberoi GS. Genito-urinary anomalies in arthrogryposis multiplex congenita. *Br J Urol* 1987;60:276–8.

- [7] Coelho KE, Sarmiento MF, Veiga CM, Speck-Martins CE, Safatle HP, Castro CV, et al. Misoprostol embryotoxicity: clinical evaluation of fifteen patients with arthrogryposis. *Am J Med Genet* 2000;95:297–301.
- [8] Quinn CM, Wigglesworth JS, Heckmatt J. Lethal arthrogryposis multiplex congenita: a pathological study of 21 cases. *Histopathology* 1991;19:155–62.
- [9] Hall JG. Arthrogryposis multiplex congenita: etiology, genetics, classification, diagnostic approach, and general aspects. *J Pediatr Orthop B* 1997;6:159–66.
- [10] Abrams P, Cardozo L, Fall M, Griffiths D, Rosier P, Ulmsten U, et al. The standardisation of terminology of lower urinary tract function: report from the standardisation subcommittee of the International Continence Society. *Neuro-urol Urodyn* 2002;21:167–78.
- [11] Bankhead RW, Kropp BP, Cheng EY. Evaluation and treatment of children with neurogenic bladders. *J Child Neurol* 2000;15:141–9.
- [12] Merenda L, Brown JP. Bladder and bowel management for the child with spinal cord dysfunction. *J Spinal Cord Med* 2004;27(Suppl. 1):S16–23.
- [13] Singh SK, Singh RD, Sharma A. Caudal regression syndrome—case report and review of literature. *Pediatr Surg Int* 2005;21:578–81.
- [14] Banker BQ. Arthrogryposis multiplex congenita: spectrum of pathologic changes. *Hum Pathol* 1986;17:656–72.
- [15] Hall JG. Genetic aspects of arthrogryposis. *Clin Orthop Relat Res* 1985;194:44–53.
- [16] Bharucha EP, Pandya SS, Dastur DK. Arthrogryposis multiplex congenita. I. Clinical and electromyographic aspects. *J Neurol Neurosurg Psychiatr* 1972;35:425–34.
- [17] Gaitanis JN, McMillan HJ, Wu A, Darras BT. Electrophysiologic evidence for anterior horn cell disease in amyoplasia. *Pediatr Neurol* 2010;43:142–7.
- [18] Goksen D, Darcan S, Coker M, Aksu G, Yildiz B, Kara S, et al. Permanent neonatal diabetes with arthrogryposis multiplex congenita and neurogenic bladder – a new syndrome? *Pediatr Diabetes* 2006;7:279–83.
- [19] Landau D, Mishori-Dery A, Hershkovitz R, Narkis G, Elbedour K, Carmi R. A new autosomal recessive congenital contractural syndrome in an Israeli Bedouin kindred. *Am J Med Genet A* 2003;117A:37–40.