

# Oral Pentoxifylline Combined with Pentavalent Antimony: A Randomized Trial for Mucosal Leishmaniasis

Paulo R. L. Machado,<sup>1</sup> Hélio Lessa,<sup>1</sup> Marcus Lessa,<sup>1</sup> Luiz H. Guimarães,<sup>1</sup> Heejung Bang,<sup>2</sup> John L. Ho,<sup>2</sup> and Edgar M. Carvalho<sup>1</sup>

<sup>1</sup>Serviço de Imunologia, Hospital Universitário Prof. Edgard Santos, Universidade Federal da Bahia, Salvador-Bahia, Brazil; and <sup>2</sup>Division of International Medicine and Infectious Diseases of the Department of Medicine, Division of Biostatistics and Epidemiology of the Department of Public Health, Weill Medical College of Cornell University, New York, New York

**Background.** Mucosal leishmaniasis is associated with intense tissue damage and high tumor necrosis factor- $\alpha$  production. Therapeutic failure occurs in up to 42% of cases; patients who experience treatment failure will require >1 pentavalent antimony (Sb<sup>v</sup>) course or alternative drugs to achieve a cure. We previously showed that an inhibitor of tumor necrosis factor- $\alpha$  (pentoxifylline) combined with Sb<sup>v</sup> cured 90% patients refractory to monotherapy with Sb<sup>v</sup>.

**Methods.** A double-blind, placebo-controlled trial involving 23 patients with mucosal leishmaniasis evaluated the efficacy of pentoxifylline when administered in association with Sb<sup>v</sup>, compared with Sb<sup>v</sup> treatment alone. Eleven patients were randomized to receive Sb<sup>v</sup> plus oral pentoxifylline for 30 days, and 12 patients received Sb<sup>v</sup> plus oral placebo. The criterion for cure was a complete healing of lesions.

**Results.** All patients in the pentoxifylline group experienced a cure with 1 course of Sb<sup>v</sup>, whereas 5 (41.6%) of 12 patients in the placebo group required a second course of Sb<sup>v</sup> ( $P = .037$ ). The healing time  $\pm$  standard deviation in the pentoxifylline group was  $83 \pm 36$  days, compared with  $145 \pm 99$  days in the placebo group ( $P = .049$ ). No relapses were documented in either group at the 2-year follow-up visit.

**Conclusions.** The addition of pentoxifylline to Sb<sup>v</sup> in mucosal leishmaniasis reduces the healing time significantly and prevents the need for further courses of Sb<sup>v</sup>.

Leishmaniasis are protozoan-caused diseases that have worldwide distribution and an overall prevalence of 12 million cases at present [1]. It is estimated that 350 million individuals are at risk for infection with *Leishmania* species, which results in an annual incidence of 1–1.5 million cases of cutaneous leishmaniasis and 500,000 cases of visceral leishmaniasis [1]. In Central and South America, cutaneous leishmaniasis is a major public health problem; in an area of endemicity in south Bahia, Brazil, cutaneous leishmaniasis caused by *Leishmania braziliensis* has an annual rate of incidence of 8.1 cases per 1000 persons [2]. It is estimated that

mucosal leishmaniasis develops in ~3% of all patients who have cutaneous leishmaniasis that is caused by *L. braziliensis*. The mucosal disease is observed concomitantly with or months to years after the cutaneous disease and is characterized by the presence of destructive lesions that predominantly affect the nose [2, 3]. Complications include nasal septum perforation, vocal cord involvement with hoarseness, and deformity of the nasal pyramid. Upper respiratory tract obstruction leading to death has been reported [3]. The standard treatment for mucosal leishmaniasis is high-dose pentavalent antimony (Sb<sup>v</sup>; 20 mg per kg of body weight per day for 30 days), [4]; clinical treatment failure occurs in up to 42% of cases [5]. Moreover, relapses may occur in as many as 19% of patients after 3–10 years of follow-up [6]. These patients will require further courses of Sb<sup>v</sup> or amphotericin B to achieve cure. Better therapeutic approaches that are associated with lower rates of failure and relapse are essential for the control of mucosal leishmaniasis. Despite the paradigm that a

Received 29 August 2006; accepted 13 November 2006; electronically published 2 February 2007.

Reprints or correspondence: Edgar M. Carvalho, Hospital Universitário Prof. Edgard Santos, Serviço de Imunologia, 5º andar, Rua João das Botas s/n, Canela 40110-160, Salvador-Bahia, Brazil (imuno@ufba.br).

**Clinical Infectious Diseases** 2007;44:788–93

© 2007 by the Infectious Diseases Society of America. All rights reserved.

1058-4838/2007/4406-0005\$15.00

DOI: 10.1086/511643

Th1-type immune response is necessary for the control and cure of *Leishmania* infection, cutaneous and mucosal diseases have been considered to be inflammatory reactions that are mediated by host immune response. Evidence for the role of the immune response in the pathogenesis of mucosal leishmaniasis includes (1) the presence of inflammatory infiltrate despite the paucity of parasites in culture or biopsy samples [7], (2) high levels of IFN- $\gamma$  and TNF- $\alpha$  in PBMCs [8–10] and increased expression of these mediators in tissue [11], and (3) a decreased ability of IL-10 to down-regulate levels of the exaggerated inflammatory response [12]. We have previously shown in an open-label study that 90% of patients who had severe mucosal leishmaniasis that was refractory to Sb<sup>v</sup> alone were cured when treated with an inhibitor of TNF- $\alpha$  (pentoxifylline) and Sb<sup>v</sup> [13]. The following study is a randomized, double-blind trial comparing standard Sb<sup>v</sup> treatment for mucosal leishmaniasis plus a placebo versus Sb<sup>v</sup> combined with pentoxifylline. Time to clinical cure, as well as absolute cure rate at 90 days after treatment, were measured. Patients were observed for up to 2 years.

## PATIENTS AND METHODS

**Study design and patient selection.** This randomized, double-blind, placebo-controlled trial involved 23 patients with mucosal leishmaniasis who were living in Corte de Pedra, an area of endemicity of *L. braziliensis* transmission that is located in the southern part of the state of Bahia, Brazil. This site is a reference center for the diagnosis and treatment of cutaneous and mucosal leishmaniasis. The objective of this study was to evaluate the efficacy of the combined therapy of Sb<sup>v</sup> with pentoxifylline compared with Sb<sup>v</sup> plus placebo for the treatment of mucosal leishmaniasis.

Patients who were eligible for enrollment after providing informed consent were aged 18–65 years and had severe mucosal leishmaniasis (defined as the presence of deep mucosal ulcers and/or septal infiltration or perforation). A clinical diagnosis was confirmed by at least 2 of the following laboratory methods: a positive intradermal skin test result with *Leishmania* antigen, parasite isolation by culture, or histopathological findings characteristic of mucosal leishmaniasis. The *Leishmania* antigen that was used for the intradermal skin test was obtained from a strain of *Leishmania amazonensis* (MHOM-BR-86BA-125); 25  $\mu$ g of antigen in 0.1 mL of solution was injected into the skin of the forearm [14]. The indurated area was measured after 48 h, and a reaction was considered to be positive if the measurement was >5 mm in diameter. Patients who had superficial mucosal ulcers (mild mucosal leishmaniasis), prior therapy for mucosal disease, diabetes, or coinfection with HIV, or who were unavailable to follow-up, were excluded from the study. This study was approved by the ethical committee for

research of the Hospital Universitário Prof. Edgard Santos, Salvador-Bahia, Brazil.

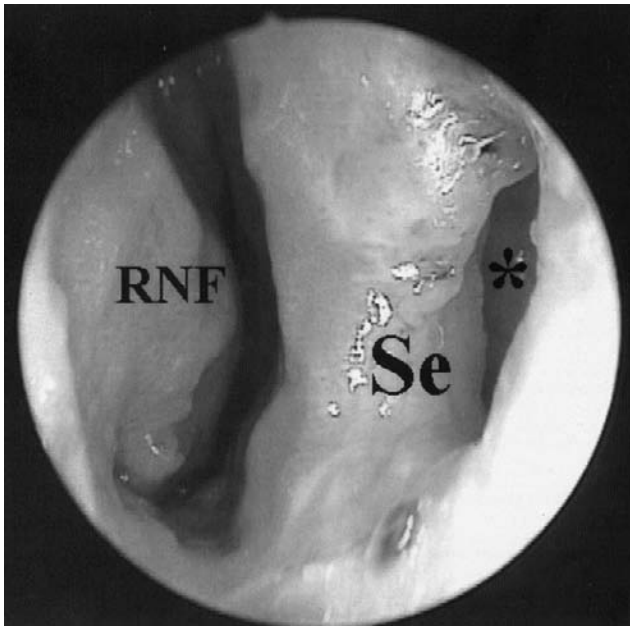
**Treatment.** After consent was obtained, patients were randomized, through the use of a randomization table, to the combined treatment group or the control group. Both the otolaryngologist and participants were blinded to treatment assignment during all the steps of the study, including the follow-up period. Patients with mucosal leishmaniasis received intravenous Sb<sup>v</sup> (meglumine antimony; Aventis), at a dosage of 20 mg per kg of body weight per day, plus oral pentoxifylline (Pentox; Farmasa) at a dosage of 400 mg 3 times daily for 30 days. Patients allocated to the control group received the same Sb<sup>v</sup> schedule plus oral placebo pills that were formulated to appear identical to pentoxifylline 3 times daily for 30 days. A data safety monitoring committee had access to patient assignment in the event of adverse events. No patient received previous antileishmaniasis treatment.

**Efficacy assessments.** All patients were evaluated every 30 days by a blinded otolaryngology specialist. The primary end point was cure, defined as complete reepithelization of the mucosal tissue and no evidence of inflammatory activity in the 150 days after initiation of therapy. An interim analysis was performed at 90 days after initiation of therapy. Patients who became worse or who had no change in the characteristics of their lesions received a second course of Sb<sup>v</sup>. Patients who demonstrated partial but not complete healing at 90 days after initiation of therapy were further evaluated for another 30–60 days, and those who did not experience complete healing underwent another round of treatment. Secondary end points were the healing time of the mucosal lesion and no evidence of relapse after 2 years of follow-up.

**Statistical analysis.** We adopted nonparametric tests for all statistical analyses because our sample size was not large enough to justify standard asymptotical theories. Patients' characteristics and medical profiles at randomization, as well as during the follow-up period, were summarized by median, mean  $\pm$  SD, or percentage, and were compared between the 2 groups using Fisher's exact test (for categorical variables) and the Wilcoxon test or the Mann-Whitney *U* test (for continuous variables). A Kaplan-Meier curve, coupled with the log-rank test, was used to evaluate the rates of cure. Pearson correlation between duration of symptoms and cure status or *Leishmania* skin test reaction size was performed.

## RESULTS

All patients who were enrolled in this study had severe mucosal leishmaniasis with nasal involvement that consisted of granulomatous infiltration and septal perforation or deep ulcer (figure 1). Patients who were administered placebo plus Sb<sup>v</sup> or pentoxifylline plus Sb<sup>v</sup> did not differ in any of the baseline characteristics examined—an indication of the proper imple-



**Figure 1.** Clinical appearance of mucosal leishmaniasis in a representative case. Mucosal leishmaniasis with granulomatous infiltration in the right nasal fossa and septal perforation in an enrolled patient at time of randomization. \*Septal perforation. RNF, right nasal fossa; Se, septum.

mentation of randomization (table 1). The duration of symptoms, mainly characterized by nasal obstruction, was slightly shorter in the group who received combined pentoxifylline plus  $Sb^v$  therapy, but it was not significantly different from the control group. To evaluate the influence of the duration of the symptoms on the time to cure, we computed the Pearson correlation coefficient between the duration of symptoms and cure status at 6 months. The correlation coefficient between the duration of symptom and cure status was 0.077 ( $P = .75$ ). Thus, there was no significant association between these factors. The *Leishmania* skin test results had slightly higher values for a larger diameter in the control group (median diameter  $\pm$  SD,  $25 \pm 10$  mm) than the pentoxifylline group (mean diameter  $\pm$  SD,  $19 \pm 4$  mm), as well as for the corresponding areas of the reaction site (mean area  $\pm$  SD,  $634 \pm 485$  mm<sup>2</sup> vs.  $355 \pm 166$  mm<sup>2</sup>), but none of these differences are statistically significant. We also evaluated whether the duration of symptoms may correlate with a more intense immunological response of the *Leishmania* skin test as a surrogate marker for host inflammatory response. The Pearson correlation coefficient between the duration of symptoms and the skin test result was 0.15 ( $P = .57$ ).

Next, we evaluated clinical cure response as defined by complete reepithelization of the mucosa (figure 2). In the pentoxifylline group, 9 (82%) of 11 patients were cured within 90 days after onset of therapy. In the same period, only 5 (41.6%) of 12 patients in the placebo group were cured during this time.

Evaluation at day 120 and day 150 after treatment initiation showed no cases of active disease in the pentoxifylline group, whereas 5 patients in the placebo group did not achieve cure and required a second course of  $Sb^v$  ( $P = .037$ ) (table 1). Patients who were treated with pentoxifylline plus  $Sb^v$  healed significantly faster than patients who were treated with placebo plus  $Sb^v$  (mean  $\pm$  SD,  $83 \pm 36$  days vs.  $145 \pm 99$  days;  $P = .049$ ). A Kaplan-Meier curve (figure 3) shows that the proportion of patients who had continued disease was significantly greater in the control group than in the pentoxifylline group ( $P = .047$ , by the log-rank test). No relapses were documented during the follow-up period of at least 2 years after treatment cessation.

Mild adverse effects were observed more frequently in the  $Sb^v$  plus pentoxifylline group, including nausea (3 patients); arthralgias (1 patient); and dizziness, abdominal pain, and diarrhea (1 patient). In the group treated with placebo and  $Sb^v$ , 1 patient complained of anorexia, nausea, and myalgias. No patients in either group discontinued treatment because of these adverse effects.

## DISCUSSION

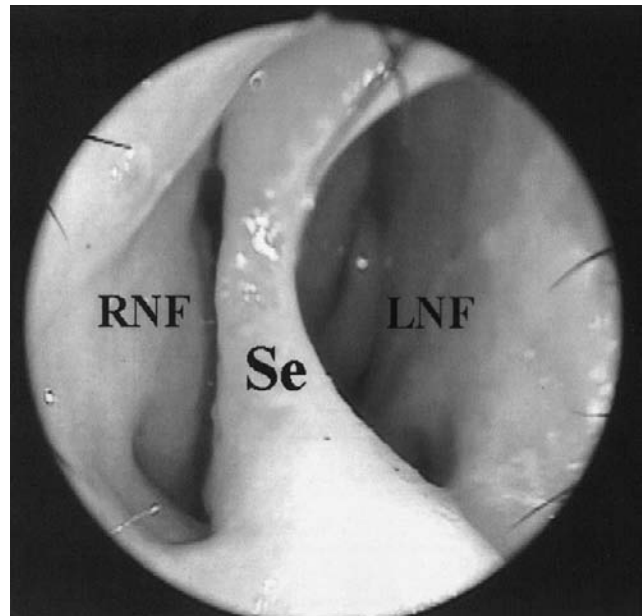
For mucosal leishmaniasis caused predominantly by *L. braziliensis* that is treated with  $Sb^v$  (which is the standard drug treatment for leishmaniasis), the high treatment failure rate or relapse rate of disease is a major problem [5, 6]. Amphotericin B is an effective treatment for mucosal leishmaniasis, but the severe adverse effects and the need for hospitalization to administer the drug increase the cost and limit its use, particularly in the rural areas where mucosal leishmaniasis occurs most frequently. Therefore, the development of a more effective treatment for mucosal leishmaniasis is a major goal. This randomized, double-blind, placebo-controlled clinical trial demonstrates that pentoxifylline combined with  $Sb^v$  significantly accelerates the healing time of mucosal leishmaniasis. In addition, patients with mucosal leishmaniasis who were treated with this combination experienced a 100% rate of cure with 1 course of treatment, compared with the 58% cure rate that was observed in the control group. No early relapses of leishmaniasis were seen during a minimum follow-up duration of 2 years.

Mucosal leishmaniasis has a spectrum of clinical presentation that ranges from nodular lesions to deep ulcers that, when localized in the septum, can lead to perforation. It is known that disease duration and intensity of the inflammatory response may also influence therapeutic responses. In this study, there were no significant differences observed between the 2 groups regarding duration of illness, severity of disease, and inflammatory response measured by the delayed hypersensitivity *Leishmania* skin test. Previous studies involving hamsters with *Leishmania vianna panamensis* infection [15] showed that

infection in male animals resulted in significantly greater lesions and severity of disease. Despite the fact that, in our study, there were more male patients in the placebo group than in the pentoxifylline group, no statistically significant difference was observed, making it unlikely that this variable influenced the therapeutic response.

The evidence for the role of the immune response in the pathogenesis of cutaneous and mucosal leishmaniasis has implications for the therapy of these infectious diseases. It is clear that a Th1-type immune response with IFN- $\gamma$  production and nitric oxide synthesis by macrophages is necessary to kill *Leishmania* species [8]. Nonetheless, patients who have mucosal leishmaniasis develop disease despite a strong cellular immune response [16]. There is evidence that parasites remain in the host after resolution of disease [17] and that the tissue damage that is observed in mucosal leishmaniasis is related to an unmodulated immune response with increased production of proinflammatory cytokines and a lack of effector or regulatory function by cytokines, such as IL-10 [12]. The concept that *L. braziliensis* infection may trigger an intense and persistent immune response with an unmodulated and heightened level of a proinflammatory component suggests a role for immunomodulators in the therapy of leishmaniasis. Furthermore, agents that primarily affect the immune system, such as granulocyte macrophage colony-stimulating factor and pentoxifylline, have been reported to accelerate the healing time of cutaneous leishmaniasis [18, 19] and to cure mucosal leishmaniasis that is refractory to Sb<sup>v</sup> therapy [13], respectively. Our report extends the use of pentoxifylline to the more severe form of leishmaniasis: severe mucosal disease.

Pentoxifylline is a methylxanthine that was originally licensed



**Figure 2.** Complete reepithelization of the mucosa and septal perforation in the patient from figure 1 within 90 days after onset of therapy with pentoxifylline plus pentavalent antimony (Sb<sup>v</sup>). LNF, left nasal fossa; RNF, right nasal fossa; Se, septum.

in the United States for the treatment of peripheral vascular disease [20], but it has recently been used experimentally for a number of inflammatory conditions [21–23]. We have previously shown that pentoxifylline added to Sb<sup>v</sup> is effective in the treatment of mucosal leishmaniasis that is unresponsive to standard Sb<sup>v</sup> treatment [13]. There has also been a report of 2 patients who were successfully treated for refractory cutaneous

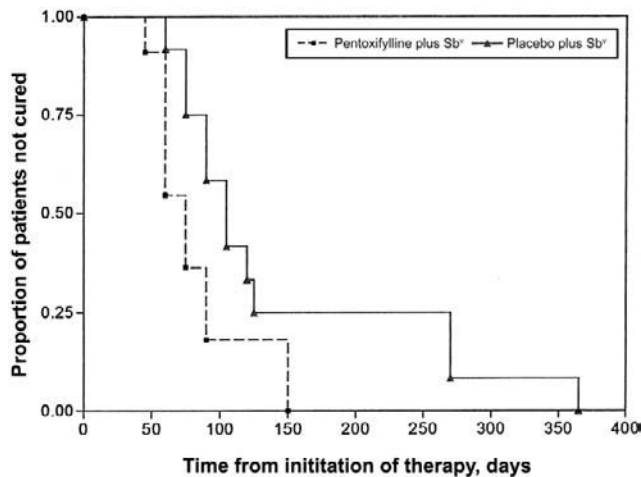
**Table 1. Characteristics and clinical response of patients with mucosal leishmaniasis, by treatment arm.**

| Characteristic  | Treatment arm                            |   | P <sup>a</sup> |
|---|--|---|----------------|
|   | Placebo plus Sb <sup>v</sup><br>(n = 12) | Pentoxifylline plus Sb <sup>v</sup><br>(n = 11) |                |
| Age in years, median (mean $\pm$ SD)                                  | 40 (42 $\pm$ 14)                         | 32 (37 $\pm$ 15)                                | .40            |
| Female patients, %  | 8  | 27  | .32            |
| Patients with previous cutaneous leishmaniasis, %                     | 75                                       | 64  | .67            |
| Duration of symptoms, months  |  |   |                |
| Median (mean $\pm$ SD)  | 12 (50 $\pm$ 79)                         | 6 (18 $\pm$ 36)                                 | .25            |
| Range   | 2–240                                    | 0.5–120   |                |
| Leishmania skin test result   |  |   |                |
| Largest induration diameter measurement, median mm (mean mm $\pm$ SD) | 22 (25 $\pm$ 10)                         | 20 (19 $\pm$ 4)                                 | .13            |
| Area, median mm <sup>2</sup> (mean mm <sup>2</sup> $\pm$ SD)          | 451 (634 $\pm$ 485)                      | 352 (355 $\pm$ 166)                             | .11            |
| Follow-up, median months (mean months $\pm$ SD)                       | 27 (28 $\pm$ 9)                          | 23 (27 $\pm$ 10)                                | .17            |
| Time to cure, median days (mean days $\pm$ SD)                        | 105 (145 $\pm$ 99)                       | 75 (83 $\pm$ 36)                                | .049           |
| Patients who received a second course of Sb <sup>v</sup> , %          | 42                                       | 0   | .037           |

**NOTE.** Sb<sup>v</sup>, pentavalent antimony.

<sup>a</sup> P value was computed using the Mann-Whitney U test and Fisher's exact test for continuous and categorical variables, respectively.





**Figure 3.** Kaplan-Meier estimates of the proportion of patients not cured with pentoxifylline plus pentavalent antimony (Sb<sup>v</sup>) treatment or placebo plus Sb<sup>v</sup> treatment ( $P = .047$ , by the log-rank test; and  $P = .031$ , by the Wilcoxon test).

leishmaniasis with pentoxifylline added to Sb<sup>v</sup> [24], and combined therapy with Glucantime (Aventis) and pentoxifylline was considered to be more effective than Glucantime alone in Old World cutaneous leishmaniasis [25]. This report suggests that pentoxifylline also has a role in the therapy of treatment-naïve patients who have severe mucosal leishmaniasis. Because pentoxifylline is known to downregulate TNF- $\alpha$  production [26], it is possible that this mechanism is responsible for the clinical improvement that is observed. The inhibition of TNF- $\alpha$  production is also a therapeutic approach in the control of erythema nodosum leprosum [27], where the use of pentoxifylline has also been indicated [28]. In our open-label study involving 10 patients with mucosal leishmaniasis whose disease was refractory to at least 3 previous courses of Sb<sup>v</sup> therapy, we observed that pentoxifylline plus Sb<sup>v</sup> significantly decreased TNF- $\alpha$  levels and resulted in a cure in 9 patients [13]. The present study extends the therapeutic usefulness of this treatment combination for previously untreated severe mucosal leishmaniasis. As such, pentoxifylline, when added to Sb<sup>v</sup>, may result in a higher cure rate and a faster healing time for mucosal lesions. Pentoxifylline combined with Sb<sup>v</sup> is, therefore, a therapeutic choice for patients with mucosal leishmaniasis who have advanced forms of the disease.

### Acknowledgments

We thank Mrs. Elbe M. Silva for secretarial assistance, Ednaldo Lima do Lago for field assistance, and Drs. Warren Johnson and Daniel Morgan for suggestions and revision of the text.

**Financial support.** Howard Hughes Medical Institute (International Scholars Research Grant) and Fundação de Amparo à Pesquisa do Estado da Bahia.

**Potential conflicts of interest.** All authors: no conflicts.

### References

- Desjeux P. Leishmaniasis: current situation and new perspectives. *Comp Immunol Microbiol Infect Dis* **2004**; 27:305–18.
- Jones TC, Johnson WD Jr, Barreto AC, et al. Epidemiology of American cutaneous leishmaniasis due to *Leishmania braziliensis braziliensis*. *J Infect Dis* **1987**; 156:73–83.
- Marsden PD. Mucosal leishmaniasis due to *Leishmania (Viannia) braziliensis* L(V)b in Três Braços, Bahia-Brazil. *Rev Soc Bras Med Trop* **1994**; 27:93–101.
- Berman JD. Chemotherapy for leishmaniasis: biochemical mechanisms, clinical efficacy, and future strategies. *Rev Infect Dis* **1988**; 10:560–86.
- Franke ED, Wignall FS, Cruz ME, et al. Efficacy and toxicity of sodium stibogluconate for mucosal leishmaniasis. *Ann Intern Med* **1990**; 113: 934–40.
- Netto EM, Marsden PD, Llanos-Cuentas EA, et al. Long-term follow-up of patients with *Leishmania (Viannia) braziliensis* infection and treated with glucantime. *Trans R Soc Trop Med Hyg* **1990**; 84:367–70.
- Bittencourt AL, Andrade ZA. Immunopathological aspects of mucocutaneous leishmaniasis. *Hospital (Rio J)* **1967**; 71:975–84.
- Ribeiro de Jesus A, Almeida RP, Lessa H, Bacellar O, Carvalho EM. Cytokine profile and pathology in human leishmaniasis. *Braz J Med Biol Res* **1998**; 31:143–8.
- Da-Cruz AM, Oliveira MP, De Luca PM, Mendonça SCE, Coutinho SG. Tumor necrosis factor-alpha in human American tegumentary leishmaniasis. *Mem Inst Oswaldo Cruz* **1996**; 91:225–9.
- Castés M, Trujillo O, Rojas ME, et al. Serum levels of tumor necrosis factor in patients with American cutaneous leishmaniasis. *Biol Res* **1993**; 26:233–8.
- Pirmez C, Yamamura M, Uyemura K, Paes-Oliveira M, Conceição-Silva F, Modlin RL. Cytokine patterns in the pathogenesis of human leishmaniasis. *J Clin Invest* **1993**; 91:1390–5.
- Bacellar O, Lessa H, Schriefer A, et al. Up-regulation of Th-1 responses in mucosal leishmaniasis patients. *Infect Immun* **2002**; 70:6734–40.
- Lessa HA, Machado P, Lima F, et al. Successful treatment of refractory mucosal leishmaniasis with pentoxifylline plus antimony. *Am J Trop Med Hyg* **2001**; 65:87–9.
- Reed SG, Badaró R, Masur H, et al. Selection of a skin test antigen for American cutaneous leishmaniasis. *Am J Trop Med Hyg* **1986**; 35: 79–85.
- Travi BL, Osorio Y, Melby PC, Chandrasekar B, Arteaga L, Saravia NG. Gender is a major determinant of the clinical evolution and immune response in hamsters infected with *Leishmania* spp. *Infect Immun* **2002**; 70:2288–96.
- Carvalho EM, Johnson WD, Barreto E, et al. Cell mediated immunity in American cutaneous and mucosal leishmaniasis. *J Immunol* **1985**; 135:4144–8.
- Mendonça MG, de Brito ME, Rodrigues EH, Bandeira V, Jardim ML, Abath FG. Persistence of *Leishmania* parasites in scars after clinical cure of American cutaneous leishmaniasis: is there a sterile cure? *J Infect Dis* **2004**; 189:1018–23.
- Almeida R, D'Oliveira A Jr, Machado P, et al. Randomized, double-blind study of stibogluconate plus human granulocyte macrophage colony-stimulating factor versus stibogluconate alone in the treatment of cutaneous leishmaniasis. *J Infect Dis* **1999**; 180:1735–7.
- Santos JB, de Jesus AR, Machado PR, et al. Antimony plus recombinant human granulocyte-macrophage colony-stimulating factor applied topically in low doses enhances healing of cutaneous leishmaniasis ulcers: a randomized, double-blind, placebo-controlled study. *J Infect Dis* **2004**; 190:1793–6.
- Ward A, Clissold SP. Pentoxifylline: a review of its pharmacodynamic and pharmacokinetic properties, and its therapeutic efficacy. *Drugs* **1987**; 34:50–98.
- Das BK, Mishra S, Padhi PK, et al. Pentoxifylline adjunct improves prognosis of human cerebral malaria in adults. *Trop Med Int Health* **2003**; 8:680–4.

22. Gutierrez-Reyes G, Lopez-Ortal P, Sixtos S, et al. Effect of pentoxifylline on levels of pro-inflammatory cytokines during chronic hepatitis C. *Scand J Immunol* **2006**; 63:461–7.
23. Ustunsoy H, Sivrikoz MC, Tarakcioglu M, Bakir K, Guldur E, Celkan MA. The effects of pentoxifylline on the myocardial inflammation and ischemia-reperfusion injury during cardiopulmonary bypass. *J Card Surg* **2006**; 21:57–61.
24. Bafica A, Oliveira F, Freitas LA, Nascimento EG, Barral A. American cutaneous leishmaniasis unresponsive to antimonial drugs: successful treatment using combination of N-methylglucamine antimoniate plus pentoxifylline. *Int J Dermatol* **2003**; 42:203–7.
25. Sadeghian G, Nilforoushzadeh MA. Effect of combination therapy with systemic Glucantime and pentoxifylline in the treatment of cutaneous leishmaniasis. *Int J Dermatol* **2006**; 45:819–21.
26. Doherty GM, Jensen JC, Alexander HR, Buresh CM, Norton JA. Pentoxifylline suppression of tumor necrosis factor gene transcription. *Surgery* **1991**; 110:192–8.
27. Sarno EN, Grau GE, Vieira IMM, Nery JAC. Serum levels of tumour necrosis factor–alpha and interleukin-1 beta during leprosy reactional states. *Clin Exp Immunol* **1991**; 84:103–8.
28. De Carsalade GY, Achirafi A, Flageul B. Pentoxifylline in the treatment of erythema nodosum leprosum. *J Dermatol* **2003**; 30:64–8.