

# Evaluation of panoramic radiomorphometric indices related to low bone density in sickle cell disease

F. S. Neves · L. S. A. F. Oliveira · M. G. G. Torres · M. B. P. Toralles ·  
M. C. B. O. da Silva · M. I. G. Campos · P. S. F. Campos · I. Crusoé-Rebello

Received: 2 June 2011 / Accepted: 4 August 2011 / Published online: 18 October 2011

© International Osteoporosis Foundation and National Osteoporosis Foundation 2011

## Abstract

**Summary** In sickle cell disease, erythroid hyperplasia causes trabecular destruction leading to low bone density. This condition could be suspected by the radiomorphometric indices and your diagnosis becomes relevant in a multidisciplinary context of health care for sickle cell subjects, providing prognostics and contributing to determine adequate therapeutic and preventive actions.

**Introduction** The aim of this study was to assess the risk of low bone density in subjects with sickle cell disease (SCD) through analysis of panoramic radiographic exams by radiomorphometric indices.

**Methods** Seventy-eight Brazilian subjects with SCD took part in this study and were subdivided into four groups: (I) 31 SCD subjects aged under 40 years; (II) 13 SCD subjects aged 40 years or more; (III) 12 normal subjects aged under 40 years; and (IV) 22 normal subjects aged 40 years or more. In the panoramic radiographs, the mandibular cortical index (MCI) classification, increased spacing of the trabecular bone, panoramic mandibular index (PMI), and mental index (MI) were evaluated. Exact Fisher's test was used to compare age between the different groups. Descriptive analysis of the data was performed to evaluate the simple visual estimation of low bone density (increased bone trabecular space and MCI), and a one-way analysis of variance (Bonferroni criteria) was used to compare the means of the quantitative indices (PMI and MI). The significance level was  $p < 0.05$ .

**Results** In the MCI classification, C2 was more prevalent, especially in groups I and IV. Increased spacing of the trabecular bone was more frequent in groups I and II. MI did not show a statistically significant difference among the groups. PMI showed a statistically significant difference only between groups III and IV.

**Conclusions** The radiomorphometric indices applied in the present study can be used on panoramic radiographs to detect the presence of low bone density in SCD subjects.

F. S. Neves (✉)

Department of Oral Diagnosis, Division of Oral Radiology,  
Piracicaba Dental School, State University of Campinas,  
Av Limeira, 901, Areião,  
Piracicaba, São Paulo, Brazil 13414-018  
e-mail: fredsampaio@yahoo.com.br

F. S. Neves · L. S. A. F. Oliveira · M. G. G. Torres ·  
P. S. F. Campos · I. Crusoé-Rebello

Department of Oral and Maxillofacial Radiology,  
School of Dentistry, Federal University of Bahia,  
Salvador, Bahia, Brazil

M. B. P. Toralles

Department of Pediatrics, Bahia Medical School,  
Federal University of Bahia,  
Salvador, Bahia, Brazil

M. C. B. O. da Silva

Professor Edgard Santos University Hospital,  
Federal University of Bahia,  
Salvador, Bahia, Brazil

M. I. G. Campos

Department of Biomorphology, Institute of Health Sciences,  
Federal University of Bahia,  
Salvador, Bahia, Brazil

**Keywords** Low bone density · Osteoporosis · Panoramic radiograph · Sickle cell disease

## Introduction

Sickle cell disease (SCD), one of the most widespread genetic disorders worldwide [1], is characterized by the polymerization of the sickle hemoglobin creating morpho-

logically abnormal erythrocytes. These cells show less flexibility and greater adherence to endothelium, causing vaso-occlusion of microcirculation [2]. Premature destruction of sickle erythrocytes leads to chronic anemia and compensatory hyperplasia of the bone marrow, resulting in increased spacing of the trabecular bone [3].

Low bone density (osteoporosis or osteopenia) is a systemic condition in which the reduction of bone mass and deterioration of its microarchitecture leads to increased bone fragility and susceptibility to fracture risk [4–6]. Several studies have demonstrated a significant relationship between low bone density and SCD [7–10], occurring more frequently in homozygotic genotype [11, 12]. Investigations have documented low bone density in children with SCD and have postulated that poor nutrition, impaired growth hormone secretion, and delayed puberty are causal factors [13–15]; however, minimal data exist for adults [8, 16]. Because patients with SCD have lower life expectation, it is hypothesized that they are at risk of suffering consequences of low bone density.

Depending on the patient's age and bone loss, alterations in the mandibular cortex may be observed as manifestations of low bone density. Radiomorphometric indices such as the mandibular cortical index (MCI) [17], panoramic mandibular index (PMI) [4], and mental index (MI) [18], have been used in panoramic radiographs to evaluate osteoporotic changes in the maxillofacial region. The asymptomatic characteristic of low bone density makes the early identification of disease and its risk factors the main challenges for researchers. Since panoramic radiograph is a simple and inexpensive exam, its application in the diagnosis of osteoporosis and osteopenia becomes relevant in a multidisciplinary context of health care for SCD patients, providing prognostics and contributing to determine adequate therapeutic and preventive actions. To the best of our knowledge, there are no reports in the literature on the application of radiomorphometric indices for osteoporosis diagnosis in subjects with SCD; therefore, this study aimed to assess the risk of low bone density in subjects with SCD through evaluation of panoramic radiographic exams by radiomorphometric indices.

## Methods

The current study was approved by the Research Ethics Committee of the School of Dentistry—Federal University of Bahia, and all participants freely signed informed consent terms. Seventy-eight Brazilian subjects with SCD took part in this study and were subdivided into four groups: (I) 31 SCD subjects aged under 40 years; (II) 13 SCD subjects aged 40 years or more; (III) 12 normal subjects aged under 40 years; and (IV) 22 normal subjects

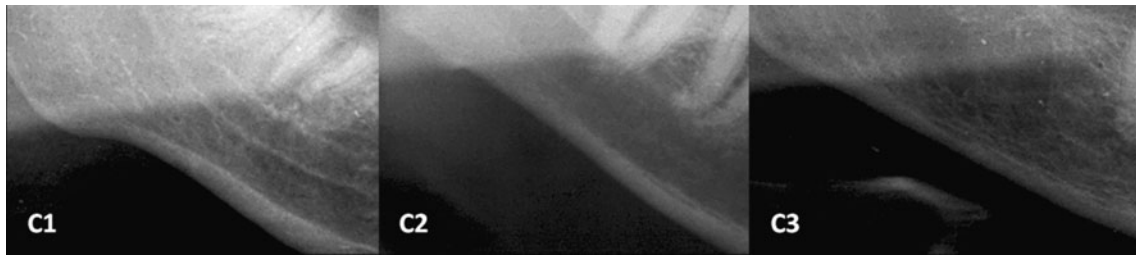
aged 40 years or more. All volunteers had their hemoglobin condition diagnosed by hemoglobin electrophoresis exam through high-performance liquid chromatography. The presence of other systemic diseases or the use of medications that could affect bone metabolism was considered as exclusion criteria in the selection of sample groups. Control group subjects were matched according to gender, age, and socioeconomic condition to subjects from test groups.

All subjects had panoramic radiographs taken as a complementary examination with their dental treatment. To be included in the study, radiographs should present technical quality criteria, and the mandible cortex should be completely visible. Thus, 22 panoramic radiographs were excluded from the study for not having such criteria.

All panoramic radiographs were obtained using the Rotograph Plus<sup>®</sup> machine (Vila Sistemi Medicali, Buccinasco, Italy), operating at 60–75 kV and 10 mA with an exposure time of 15 s. After the radiographic exposure, films were processed manually, following the manufacturer's recommendations, with new and fresh chemical solutions (Kodak-Pathé, Paris, France). The radiographs were digitized using a scanner with a transparency reader (HP Scanjet 4890 Photo Scanner) and exported in TIFF format without data compression. Images of acceptable technical quality, allowing good visualization of the radiographic features assessed, were included in the study.

Linear measurements were made in all panoramic radiographs using the RadioImp<sup>®</sup> software (Radio Memory Ltda., Belo Horizonte, Minas Gerais, Brazil) after correction for 20% magnification (to better simulate the clinical situation). An oral and maxillofacial radiologist with more than 15 years of experience evaluated the images under dim light conditions and without prior knowledge of the hematological diagnosis, age, or gender of the patients. Neither task-specific filters nor the zoom tool was applied, and no image enhancement was used. The following radiomorphometric indices were assessed:

1. MCI refers to the inferior mandibular cortical thickness and is categorized into three groups: (C1) normal cortex, when the cortex endosteal margin appears even and sharp on both sides; (C2) moderately eroded cortex, when the endosteal margin shows semilunar defects (lacunar resorption) or seems to form endosteal cortical residue; and (C3) severely eroded or porous cortex, when the cortical layers form dense endosteal cortical residue and are clearly porous. (Fig. 1).
2. MI is the measurement of the cortical width at the mental foramen region. The mental foramen was identified and a line was traced that passed perpendicular to the tangent of the lower border of the mandible



**Fig. 1** Cropped panoramic radiographs showing the C1, C2, and C3 classification of MCI

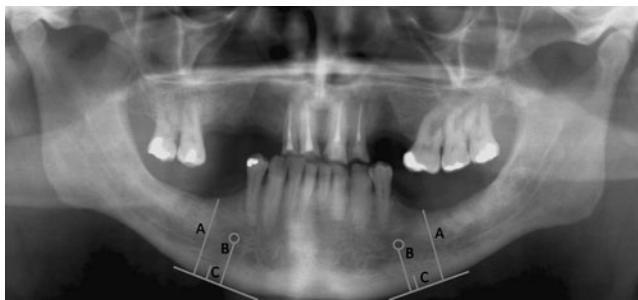and through the center of the mental foramen. The cortical width was measured at this point (Fig. 2).

3. The PMI is the ratio of the thickness of the mandibular cortex to the distance between the mental foramen and the inferior mandibular cortex (Fig. 2).
4. Increased spacing of the trabecular bone was characterized by decreased trabecular bone density and enlarged bone marrow spaces (Fig. 3).

All images were reevaluated after a 4-month interval, and intraobserver kappa agreement was calculated. Statistical analyses were performed with SAS software 9.1 (SAS Institute, Cary, NC, USA). The means and standard deviations were calculated. Exact Fisher's test was used to compare age between the different groups. Descriptive analysis of the data was performed to evaluate the simple visual estimation of low bone density (increased bone trabecular space and MCI), and a one-way analysis of variance (Bonferroni criteria) was used to compare the means of the quantitative indices (PMI and MI). The significance level was  $p < 0.05$  (Table 1).

## Results

The intraobserver kappa agreement values demonstrated high reproducibility (0.84 for MCI, 0.94 for MI, 0.91 for PMI, and 0.79 for increased spacing of the trabecular bone). In comparing groups with equivalent ages (I and III; II and



**Fig. 2** Panoramic radiograph showing the measurements in PMI (B/C) and MI (C)

IV), no significant statistical differences were observed ( $p = 0.25$ ;  $p = 0.29$ , respectively).

The PMI showed a significant statistical difference when groups III and IV were compared ( $p = 0.01$ ), indicating higher values in older subjects, even in the absence of disease. No significant statistical difference was observed when groups I and II were compared ( $p = 0.32$ ). MI did not show a significant statistical difference when the four groups were compared ( $p > 0.05$ ). According to the MCI classification, C2 was more prevalent, especially in groups I and IV. C3 was observed only in one individual, classified in group I. Independently of age, increased trabecular spacing was significantly more frequent in the sickle cell groups (I and II) when compared with the control groups (III and IV).

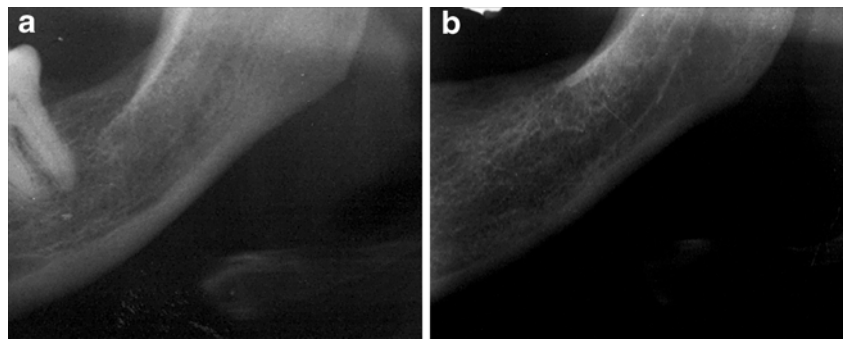
## Discussion

The skeletal system is frequently involved in patients with SCD owing to accelerated hematopoiesis and/or bone infarction. Additionally, some studies have detected the presence of low bone density in SCD subjects [7–11]. Early diagnosis of osteoporosis is important to reduce fracture risk and to initiate early treatment. Identification of the signs of osteoporosis in dental panoramic radiography is another tool in the diagnosis of this condition [19].

In a previous study, evaluation of the intraoral radiographs of 16 children under 10 years of age with SCA demonstrated increased radiolucency of the bone and a coarse trabecular pattern in 100% of the sample; none of the healthy controls presented bony changes [20]. The same radiographic features were observed in 85% of 80 individuals with SCD (5–40 years), with lower occurrence (50%) in younger children (5–10 years) and higher occurrence (100%) in adolescents (17–21 years) [21]. Visual examination of panoramic and periapical radiographs showed decreased trabecular bone density in 66.7% of patients with SCA (16–40 years) and in none of the healthy control subjects [22].

In the anterior area of the jaws, Fourier and strut analysis of periapical radiographs revealed increased trabecular

**Fig. 3** Cropped panoramic radiographs showing the normal trabecular pattern (a) and increased spacing of the trabecular bone (b)



spacing in patients with SCA when compared with the control individuals [23, 24]. Fractal analysis of panoramic radiographs revealed a scarcity of trabecular bone of the posterior mandible in patients under 20 years of age with HbSS and a high variability in fractal dimensions among patients with SCD when compared with healthy control individuals.

In the current study, the bone trabecular pattern changed in subjects with sickle cell disease, which may represent a reduction of bone density since we registered greater trabecular spacing in 51.6% and 53.8% of the subjects in groups I and II, respectively. The reason that individuals with SCD present low bone density is still uncertain. However, erythroid hyperplasia causes trabecular destruction, leading to low bone mass, and hematological causes are being implicated as a cause of osteoporosis [9].

In many studies, it has been observed by bone densitometry, especially of the lumbar spine, a high prevalence of low bone density in subjects with sickle cell anemia [9–11]. Reduction in bone density has been observed, regardless of the studied factors, when correlating with age, sex, menopause, body mass index, ferritin levels, and hemoglobin genotype in the SCD [12].

In the present study, the prevailing MCI was C2 for all the studied groups, which is consistent with the results obtained by Ledgerton et al. [18]. Only 3.3% of the subjects from group I showed the C3 index, which could indicate a greater tendency of younger subjects with this disease to develop low bone density.

The MCI is a simple method to access the mandibular inferior cortex when comparing the results of femur and lumbar spine bone densitometry and the evaluation of this area on panoramic radiographs; however, MCI is not able to detect low bone density in women [6]. Kiswanjaya et al. [25] stated that MCI may be useful in identifying patients with susceptibility to develop low bone density, although the diagnosis could be confirmed only by bone densitometry. As that index is based on a qualitative classification of the mandibular cortex, we believe that it is possible for subjectivity to influence the evaluation, in addition to the superposition of anatomic structures in this region, especially the hyoid bone, which may impair the visualization of this area on the panoramic radiograph.

In the present study, subjects from group II showed an average MI value of 3.81 mm, whereas the average MI value found in all the other groups was greater than 4 mm. It is possible that older subjects with sickle cell disease are more susceptible to developing low bone density.

According to other studies [19, 26–28], subjects with MI lower than 3 mm should be referred for bone densitometry since they have a higher propensity to develop low bone density. However, in a study conducted by Mahl et al. [29], subjects with osteopenia reached higher values of MI, with an average of 3.53 mm. Thus, subjects with MI between 3 and 4 mm must also be referred for further exams since it would allow the early detection of that systemic condition. In analyzing only the subjects with increased spacing of the trabecular bone, we observed that the lower MI values are

**Table 1** Correlation between age, PMI, MI, MCI, and increased spacing of the trabecular bone for all studied groups

Groups	Age mean (SD)	PMI mean (SD)	MI mean (SD)	MCI			Increased spacing of the trabecular bone <i>n</i> (%)
				C1 <i>n</i> (%)	C2 <i>n</i> (%)	C3 <i>n</i> (%)	
I ( <i>n</i> =31)	28.8 (6.5)a	0.30 (0.06)ab	4.04 (0.92)a	13 (41.9)	17 (54.8)	1 (3.3)	16 (51.6)
II ( <i>n</i> =13)	48.3 (8.8)a	0.32 (0.08)ab	3.81 (0.93)a	3 (23.1)	10 (76.9)	–	7 (53.8)
III ( <i>n</i> =12)	32.9 (4.3)a	0.29 (0.11)b	4.26 (0.83)a	5 (41.7)	7 (58.3)	–	1 (8.3)
IV ( <i>n</i> =22)	48.5 (7.2)a	0.38 (0.09)a	4.32 (0.99)a	9 (40.9)	13 (59.1)	–	2 (9.1)

SD standard deviation

associated with groups I and II, which indicates a greater propensity of subjects with sickle cell disease to develop low bone density. In the present study, in comparing SCD subjects with the control group, it was observed that subjects older than 40 years showed lower MI values, indicating that age is an important factor in the development of low bone density.

In the present study, the PMI values were very similar between all groups, and there was no significant statistical difference between the groups, except for group IV, in which the median was rather higher. Similar results were observed in other studies [17, 19, 30, 31], which found that patients with osteoporosis had smaller PMIs than the control group.

However, studies have demonstrated that the PMI does not show a significant statistical relationship with lumbar spine and femoral bone densitometry [32, 33]. Several factors such as the degree of severity of the SCD, overall quality of the panoramic radiographic image, and factors associated with the principles of the formation of the image (ghost images, distortion of the equipment, and uneven magnification) could affect our results. Other studies with a larger sample of SCD population should be conducted to prove this correlation.

Various factors should be considered in the present study: the individuals came from one center, which limits the generalizability of the findings; furthermore, the individuals were not subjected to bone densitometry exams. However, the current study has great clinical applicability because of the use of the panoramic radiograph, which is a widely used exam in dentistry with a low dose of exposure. Moreover, if the radiograph is not digital, the cost of the scanner and computer to evaluate the images is low compared to the cost of medical equipment used to diagnose low bone density. We believe that quick attention is needed to develop an appropriate strategy for the early diagnosis of the low bone density associated with SCD and its appropriate management.

Since SCD patients nowadays have a higher life expectancy, they may be at risk for the long-term sequelae of osteoporosis, including vertebral and hip fractures. The early diagnosis of this complication could prevent significant morbidity and increased health care costs [11]. SCD is known to cause severe bone involvement, requiring repeated hospitalization. It is anticipated that the bone involvement in SCD will further give rise to low bone mass, making the increased risk of fractures a real issue [10].

## Conclusions

We concluded that, for sickle cell subjects, there is a tendency towards lower values of PMI and MI, as well as

MCI with scores corresponding to C2, especially for older age groups. Therefore, the radiomorphometric indices applied in the present study can be used on panoramic radiographs to detect the presence of low bone density in SCD subjects.

**Acknowledgments** We are thankful to Professor Marilda Souza Gonçalves, School of Pharmacy—Federal University of Bahia, for carrying out the electrophoresis exams of the subjects and FAPESB (Bahia Research Support Foundation) for the financial support in this study.

**Conflicts of interest** None.

## References

- Creary M, Williamson D, Kulkarni R (2007) Sickle cell disease: current activities, public health implications, and future directions. *J Womens Health (Larchmt)* 16:575–582
- Steinberg MH (1998) Pathophysiology of sickle cell disease. *Baillieres Clin Haematol* 11:163–184
- Gurevitch O, Slavin S (2006) The hematological etiology of osteoporosis. *Med Hypotheses* 67:729–735
- Benson BW, Prihoda TJ, Glass BJ (1991) Variations in adult cortical bone mass as measured by a panoramic mandibular index. *Oral Surg Oral Med Oral Pathol* 71:349–356
- Bozic M, Hren NI (2005) Osteoporosis and mandibles. *Dentomaxillofac Radiol* 35:178–184
- Çakur B, Dagistan S, Sahin A, Harorli A, Yilmaz A (2009) Reliability of mandibular cortical index and mandibular bone mineral mass density in the detection of osteoporotic women. *Dentomaxillofac Radiol* 38:255–261
- Brinker MR, Thomas KA, Meyers SJ, Texada T, Humbert JR, Cook SD, Gitter R (1998) Bone mineral density of the lumbar spine and proximal femur is decreased in children with sickle cell anemia. *Am J Orthop (Belle Mead NJ)* 27:43–49
- Nelson DA, Rizvi S, Bhattacharyya T, Ortega J, Lachant N, Swerdlow P (2003) Trabecular and integral bone density in adults with sickle cell disease. *J Clin Densitom* 6:125–129
- Sadat-Ali M, Al Elq AH (2007) Sickle cell anaemia: is it a cause for secondary osteoporosis? *West Afr J Med* 26:134–137
- Sadat-Ali M, Al-Elq AH, Sultan O, Al-Turki H, Bukhari R, Al-Mulhim E (2008) Low bone mass due to sickle cell anemia: is it becoming a real issue? *West Afr J Med* 27:218–223
- Miller RG, Segal JB, Ashar BH, Leung S, Ahmed S, Siddique S, Rice T, Lanzkron S (2006) High prevalence and correlates of low bone mineral density in young adults with sickle cell disease. *Am J Hematol* 81:236–241
- Sarrai M, Duroseau H, D'Augustine J, Moktan S, Bellevue R (2007) Bone mass density in adults with sickle cell disease. *Br J Haematol* 136:666–672
- Soliman AT, Bererhi H, Darwish A, Alzalabani MM, Wali Y, Ansari B (1998) Decreased bone mineral density in prepubertal children with sickle cell disease: correlation with growth parameters, degree of siderosis and secretion of growth factors. *J Trop Pediatr* 44:194–198
- VanderJagt DJ, Harmatz P, Scott-Emuakpor AB, Vichinsky E, Glew RH (2002) Bioelectrical impedance analysis of the body composition of children and adolescents with sickle cell disease. *J Pediatr* 140:681–687
- Almeida A, Roberts I (2005) Bone involvement in sickle cell disease. *Br J Haematol* 129:482–490

16. Woods KF, Ramsey LT, Callahan LA, Mensah GA, Litaker MS, Kutlar A, Barbeau P, Gutin B (2001) Body composition in women with sickle cell disease. *Ethn Dis* 2001(11):30–35
17. Klemetti E, Kolmakov S, Kroger H (1994) Pantomography in assessment of the osteoporosis risk group. *Scand J Dent Res* 102:68–72
18. Ledgerton D, Horner K, Devlin H, Worthington H (1997) Panoramic mandibular index as a radiomorphometric tool: an assessment of precision. *Dentomaxillofac Radiol* 26:95–100
19. Dagistan S, Bilge OM (2010) Comparison of antegonial index, mental index, panoramic mandibular index and mandibular cortical index values in the panoramic radiographs of normal males and male patients with osteoporosis. *Dentomaxillofac Radiol* 39:290–294
20. Sanger RG, Greer RO Jr, Averbach RE (1977) Differential diagnosis of some simple osseous lesions associated with sickle-cell anemia. *Oral Surg Oral Med Oral Pathol* 43:538–545
21. Mourshed F, Tuckson CR (1974) A study of the radiographic features of the jaws in sickle-cell anemia. *Oral Surg Oral Med Oral Pathol* 37:812–819
22. Dermibaş Kaya A, Aktener BO, Unsal C (2004) Pulpal necrosis with sickle cell anaemia. *Int Endod J* 37:602–606
23. White SC, Cohen JM, Mourshed FA (2000) Digital analysis of trabecular pattern in jaws of patients with sickle cell anemia. *Dentomaxillofac Radiol* 29:119–124
24. Faber TD, Yoon DC, White SC (2002) Fourier analysis reveals increased trabecular spacing in sickle cell anemia. *J Dent Res* 81:214–218
25. Kiswanjaya B, Yoshihara A, Deguchi T, Hanada N, Miyazaki H (2010) Relationship between the mandibular inferior cortex and bone stiffness in elderly Japanese people. *Osteoporos Int* 21:433–438
26. Tagushi A, Tsuda M, Ohtsuka M, Komada I, Sanada M, Nakamoto T, Inagaki K, Nogushi T, Kudo Y, Suei Y, Tanimoto K, Bollen AM (2006) Use of dental panoramic radiographs in identifying younger postmenopausal women with osteoporosis. *Osteoporos Int* 17:387–394
27. Devlin H, Horner K (2002) Mandibular radiomorphometric indices in the diagnosis of reduced skeletal bone mineral density. *Osteoporos Int* 13:373–378
28. Gulsahi A, Yuzugullu B, Imirzalioglu P, Genç Y (2008) Assessment of panoramic radiomorphometric indices in Turkish patients of different age groups, gender and dental status. *Dentomaxillofac Radiol* 33:96–105
29. Mahl CRW, Licks R, Fontanella VRC (2008) Comparison of morphometric indices obtained from dental panoramic radiography for identifying individuals with osteoporosis/osteopenia. *Radiol Bras* 41:183–187, Article in Portuguese
30. Horner K, Devlin H (1998) The relationship between mandibular bone mineral density and panoramic radiographic measurements. *J Dent* 26:337–343
31. Gulsahi A, Paksoy CS, Ozden S, Kucuk NO, Cebeci AR, Genç Y (2010) Assessment of bone mineral density in the jaws and its relationship to radiomorphometric indices. *Dentomaxillofac Radiol* 39:284–289
32. Çankur B, Dagistan S, Sumbullu MA (2010) No correlation between mandibular and non-mandibular measurements in osteoporotic men. *Acta Radiol* 51:789–792
33. Damilakis J, Vlasidis K (2010) Have panoramic indices the power to identify women with low BMD at the axial skeleton? *Phys Med* 27:39–43