

Retinoblastoma and p53 protein expression in pre-malignant oral lesions and oral squamous cell carcinoma

MARÍLIA GERHARDT DE OLIVEIRA¹, LUCIANA MARIA PEREIRA RAMALHO², LEONILSON GAIÃO³, DANIEL HUMBERTO POZZA⁴ and RAMON ANDRADE DE MELLO^{5,6}

¹Department of Maxillofacial Surgery, School of Dentistry, Pontifical Catholic University of Rio Grande do Sul, Porto Alegre;

²Department of Pathology, School of Dentistry, Federal University of Bahia, Salvador;

³Department of Maxillofacial Surgery, School of Dentistry, Federal University of Maranhao, Imperatriz, Brazil;

⁴Department of Experimental Biology, São João Hospital, Faculty of Medicine, University of Porto;

⁵Department of Medical Oncology, Portuguese Oncology Institute; ⁶Department of Medicine,

São João Hospital, Faculty of Medicine, University of Porto, Porto, Portugal

Received January 19, 2012; Accepted April 10, 2012

DOI: 10.3892/mmr.2012.876

Abstract. The retinoblastoma (Rb) and p53 genes play a fundamental role in cell cycle mechanisms, and their deregulation is related to many steps of oral cancer carcinogenesis. This study was conducted to evaluate the expression of the p53 and Rb proteins in malignant and pre-malignant oral cavity lesions. This retrospective study was conducted at the Federal University of Bahia, Salvador, Brazil, and the Molecular Biology Laboratory of the Otorhinolaryngology Department at the University of Heidelberg, Heidelberg, Germany. Excisional biopsy samples of oral cavities were collected from patients with suspected oral lesions. The samples were processed by immunohistochemistry to be classified by a semi-quantitative score: samples with a $\leq 10\%$ positivity were considered to have weak/negative expression (-); those with 11-50% positivity, moderate expression (+); and those with $>50\%$ positivity, high expression (++). Seventy-one patients were studied (75% male; median age, 52 years; range, 24-84). Of the samples studied, 59.4% were oral squamous cell carcinoma (OSCC) and 40.6% were pre-neoplastic lesions (leukoplakia and actinic cheilitis). OSCC presented higher expression of Rb protein compared to pre-malignant lesions: 75 vs. 25% ($p < 0.001$). Pre-neoplastic lesions presented higher expression of p53 protein compared to OSCC lesions: 55.2 vs. 44.8% ($p = 0.030$). Despite the small number of samples, the expression of these cell cycle biomarkers (p53 and Rb protein) in excisional biopsies suggests that molecular lesion

assessment can determine pre-malignant lesions, and that its use may improve the clinical and surgical treatment of early lesions. Thus, p53 protein expression may be related to the early steps of carcinogenesis in OSCC. Finally, a higher Rb expression was also observed in malignant lesions.

Introduction

Head and neck cancer (HNC) accounts for 10% of all malignant tumors worldwide and 40% of those tumors are from the oral cavity (1). In this anatomical region, 90% of tumors are oral squamous cell carcinoma (OSCC). In 2008, in the US, oral cavity cancer (OCC) represented 35,310 new cases in both genders, and it was more common in males than females: 25,331 vs. 10,000 new cases (2). The estimated mortality rate is approximately 7,590 cases per year for both genders (1,2). The understanding of the many molecular mechanisms of cancer has become an important focus of oncology research worldwide, as shown by previous studies on lung (3), breast (4), colorectal and head and neck neoplasms (5).

The retinoblastoma (Rb) and p53 gene play a fundamental role in cell cycle mechanisms and their deregulation is related to many steps of oral cancer carcinogenesis. The p53 gene is considered as a tumor suppressor gene, as it inhibits the abnormal cell cycle progression, inducing apoptosis (6). The Rb gene is an oncogene and its role is to stimulate the cell cycle progression and consequently promote unregulated cell growth and carcinogenesis (7). Of note, in previous studies, the p53 phenotype has also been suggested to be associated with unfavorable outcome in squamous cell carcinoma (SCC) of the head and neck (5). Furthermore, the Rb protein and its derivatives, such as pRb2/p130, have been found to be a putative prognostic indicator for OSCC, as well as for lung and endometrial carcinoma (8). Thus, taking these data concerning the molecular pathways involved in OSCC into consideration, this study was conducted to evaluate, by immunohistochemistry, the Rb and p53 protein expression in malignant and pre-malignant oral cavity lesions.

Correspondence to: Dr Ramon Andrade de Mello, Department of Medicine, São João Hospital, Faculty of Medicine, University of Porto, Alameda Professor Hernani Monteiro, 4200-319 Porto, Portugal

E-mail: ramondemello@gmail.com or ramonmello@med.up.pt

Key words: p53, retinoblastoma, squamous cell carcinoma, mouth neoplasm, leukoplakia, mouth mucosa, biomarkers

Materials and methods

Study design. This was a retrospective study conducted at the Federal University of Bahia, Salvador, Brazil, and the Molecular Biology Laboratory of the Otorhinolaryngology Department of the University of Heidelberg, Heidelberg, Germany.

Study population and samples. The study was previously submitted to and approved by the regional ethics committee. The research was carried out according to the World Medical Association Declaration of Helsinki. Excisional biopsy samples of oral cavities were collected from patients with suspected oral lesions evaluated at the Department of Oral Pathology of the Federal University of Bahia. The samples were then sent under the appropriate conditions to the Molecular Biology Laboratory of the Otorhinolaryngology Department of the University of Heidelberg, in order for the immunohistochemical analyses to be performed.

Laboratory analysis. Semi-quantitative analysis was performed in order to assess the samples according to the criteria demonstrated in Table I (9). In order to confirm the diagnosis and morphological analysis, the histological sections were stained with H&E. Erythroplakias and leukoplakias were analyzed considering the following histological changes (9): i) regular epithelial stratification; ii) basal layer hyperplasia; iii) teardrop-shaped reticular cells; iv) increased number of mitotic figures; v) loss of polarity of basal cells; vi) increase in the nucleus/cytoplasm ratio; vii) cell hyperchromasia; viii) nuclear polymorphism; ix) enlarged nucleoli; x) reduction in intercellular adhesion; xi) keratinization of cells in the spinous layer.

The OSCCs were analyzed according to these changes: i) degree of keratinization; ii) nuclear polymorphism; iii) mitoses; iv) invasion status; v) invasion stage; vi) lymphoplasmacytic infiltrate. Each alteration attributed a score from 1 to 4 according to the intensity. Scores were totaled and then the mean between them was obtained.

Immunohistochemistry analysis. Histochemical analyses were performed at the Laboratory of Molecular Biology, Department of Otolaryngology at the University of Heidelberg. The tissues were placed in paraffin blocks and, once identified, they were sectioned at 4 μ m. One blade was used for each antibody. Immunohistochemistry was performed in conjunction with the following procedure for antigen retrieval:

Deparaffinization. The sections were deparaffinized in xylene twice at intervals of 5 min and then rehydrated with graded alcohols and deionized water.

Antigen retrieval. The sections were immersed in citrate buffer (10 mmol/l) and placed in a microwave oven for 3 min at 700 and at 200 W for 10 min, then cooled to room temperature for 20 min and washed with deionized water.

Blocking of endogenous peroxidase. The sections were immersed in 3% H₂O₂ in PBS for 10 min and again washed with PBS.

Incubation in horse serum. The sections were incubated in horse serum for 1 h, to block ligation and non-specific antigens.

Incubation of primary antibodies. The sections were incubated at 4°C overnight with anti-p53 monoclonal antibodies and anti-Rb.

Incubation of secondary antibody. The sections washed with PBS were incubated with the secondary antibody.

Incubation in ABC reagent (Vectastain Elite ABC kit; Vector, Burlingame, CA, USA). The sections were immersed in streptavidin-biotin-peroxidase at room temperature in order to extend the reaction.

Detection with DAB (DAB peroxidase kit subtract; Vector). After washing with PBS, the reaction was revealed using a chromogenic substrate (diaminobenzidine) over a period of 7 min.

Against coloration. Sections were immersed in 50 mmol NaHCO₃, after a wash with deionized water, and immersed in hematoxylin. In order to remove the dye, the sections were washed in tap water for 10 min.

Fixing. The sections were dehydrated in graded alcohols and diaphanized in xylene.

Mounting. Blades were mounted with Eukitt (O. Kindler GmbH & Co., Freiburg, Germany).

Criteria for positive immunohistochemistry staining. The results were analyzed semi-quantitatively (Fig. 1): blades with a score of $\leq 10\%$ positive cells were considered to be have weak/negative expression (-); those with a score of 11-50%, moderate expression (+), and those with a score of $>50\%$, strong expression (++)

Statistical analysis. Data were analyzed according to descriptive statistics, means were compared using parametric and non-parametric tests according to the studied variable and proportions were compared by the Chi-square or Fisher's tests using the Statistical Package for Social Sciences (SPSS), version 19.0, software. A p-value <0.05 denoted a statistically significant difference.

Results

We enrolled 71 patient samples in this study. Of those participants, 75% were male and 25% female. The median age was 52 years (range, 24-84). The histological distribution was as follows: 59.4% were OSCC and 40.6% were pre-neoplastic lesions (leukoplakia and actinic cheilitis). In Fig. 1, we present certain histological findings of patients in order to demonstrate examples of Rb and p53 protein expression by immunohistochemical assay. The statistical analysis showed that OSCC presented higher expression of Rb protein than pre-malignant lesions: 75 vs. 25%, $p < 0.001$ (Chi-square test; Fig. 1C). Furthermore, pre-neoplastic lesions presented higher expression of p53 protein than OSCC lesions: 55.2 vs. 44.8%, $p = 0.030$ (Chi-square test).

Discussion

Currently, in HNC, particularly OSCC, chemotherapy acquires an important role in the disease follow-up management (10). Of note, there are a number of predictive markers that could be used to decide on treatment options. In this regard, the most powerful predictive factors for antitumor response include TNM stage, performance status at admission and prior treatment choices (11). Patients with localized disease have a better response than those with locally/advanced or metastatic disease. Furthermore, patients with a good performance status

Table I. Morphological parameters evaluated according to Bryne *et al* (9).

Morphological parameters	Grading			
	Grade 1	Grade 2	Grade 3	Grade 4
Keratinization degree	Highly keratinized (>50% of cells)	Moderately keratinized (20-50% of cells)	Minimum keratinization (5-20% of cells)	No keratinization (0-5% of cells)
Nuclear pleomorphism	Small nuclear pleomorphism (>75% of mature cells)	Moderate nuclear pleomorphism (50-75% mature cells)	Nuclear pleomorphism abundant (25-50% mature cells)	Extreme nuclear pleomorphism (0-25% mature cells)
Invasive pattern	Invasion by tumor edge large and well-delineated	Invasion through beams, solid bands or cords	Invasion by cords or small groups (>15 cells)	Diffuse invasion of single cells or small groups (<15 cells)
Inflammatory infiltrate	High	Moderate	Low	Absent

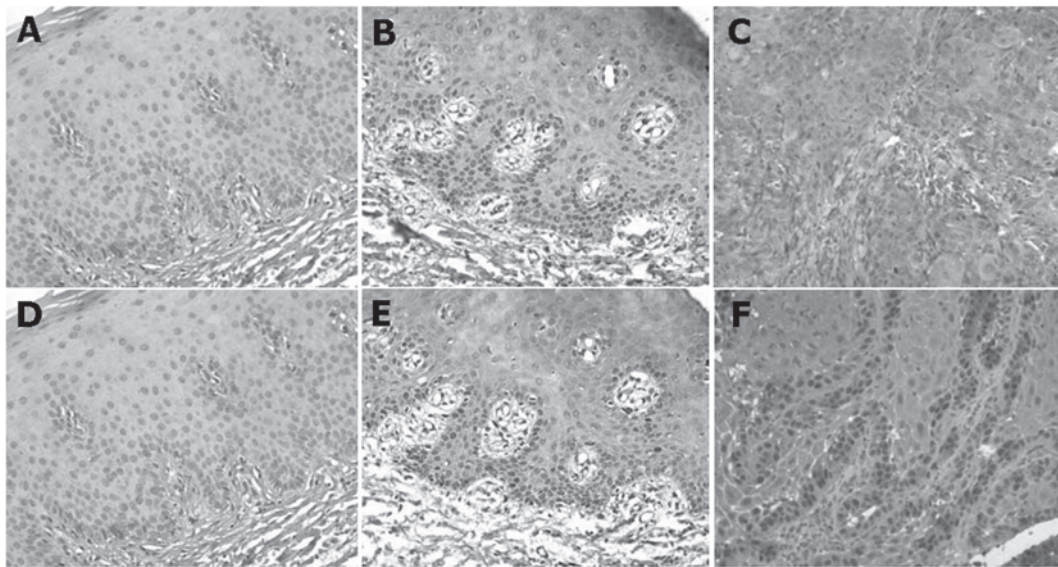


Figure 1. Examples of retinoblastoma (Rb) and p53 protein expression by immunohistochemistry. (A) Patient 68: leukoplakia; Rb (-). (B) Patient 63: leukoplakia; Rb (+). (C) Patient 25: head and neck squamous cell carcinoma; Rb (++). (D) Patient 68: leukoplakia; p53 (-). (E) Patient 63: leukoplakia; p53 (+). (F) Patient 4: lower lip tumor; p53 (++). (-), negative expression; (+), moderate expression; (++), strong expression.

are more susceptible to response than those with a bad performance status. Additionally, patients who have been extensively treated for HNC have fewer chances to respond to a new treatment choice than those who have not received treatment for HNC (11). Moreover, patients who are resistant to radiotherapy have been shown to have a particularly poor prognosis (12).

In the metastatic and recurrent setting, certain chemotherapeutic agents in combination regimens have been shown to be effective in the management of HNC, such as cisplatin/fluorouracil (5-FU), carboplatin/5-FU, cisplatin/paclitaxel, paclitaxel/ifosfamide/carboplatin and cisplatin/cetuximab (10). Thus, the understanding of the disease and the molecular mechanisms underlying OSCC have become an important focus of HNC treatment research. First, platinum, in this case cisplatin, normally acts by inducing cell death due to the development of covalent bifunctional DNA adducts with cellular DNA. Of note, mechanisms that regulate post DNA-damage, such as altered cell cycle regulation, have implications in cellular resistance to

platinum compounds (13). In this setting, the p53 and Rb expression status should play a role. Second, 5-FU is a drug that exerts cytotoxic effects via the inhibition of thymidylate-synthase (TS), by incorporation into RNA and also DNA. Furthermore, factors mediating TS downstream, such as p53 status, may influence its cellular response due to genotoxic stress (14).

Recently, human papilloma virus (HPV) was also identified as a potential inductor of OSCC carcinogenesis (15). This oncogenic virus encodes two proteins, E6 and E7, which inactivate the p53 tumor suppressor gene and Rb apoptosis/tumor suppressor gene. Thus, the subsequent genomic instability leads to uncontrolled progressive growth in cancer (15). The identification of molecular genetic activity detects lesions that may become malignant. This facilitates the clinical intervention and prevents surgical injuries (16). The expression of p53 may be associated with the development of OSCC and dysplasia, being more evident in the early stages of carcinogenesis (17) due to the lack of apoptosis and the continuous

cell division (18). In more than half of oral cancer cases, mutations in p53 have been observed (18), but the diagnostic importance of this cellular dysfunction remains uncertain due to the lack of unanimity regarding the rules which determine the forms of collection, preparation material and evaluation of results (19). However, other studies have demonstrated that p53 expression is associated with the poor prognosis of OSCC. This may be due to the functional inactivation of p53 causing defects in DNA repair and also apoptosis (20). In 2009, Shah *et al* reported that p53 is associated with relapse-free survival of OSCC patients (21). They also mentioned that p53 immunostaining serves as a potential adjunct in the pathological evaluation of oral specimens. Nevertheless, they hypothesized that this approach may be helpful in the identification of those patients with the aggressive phenotype, and that it may serve to tailor treatment regimens in future protocols. In our study, there was a higher expression of p53 protein in pre-malignant lesions than in malignant lesions. Thus, we suggest that the higher expression of p53 plays a role in oral lesion evolution. Other studies have shown conflicting results concerning the p53 and Rb expression in malignant lesions (22). However, Brunotto *et al* reported that p53 status changes between leukoplakia, oral lichen planus and oral cancer (23).

In this study, the samples used allowed the analysis of expression in the tumor process. Immunobiomarkers suggested a pre-malignant pre-determining value, but a larger sample and a complementary study, using other immunomarkers, proteomic technics and either tissue microarray techniques, are warranted in order to show more significant expression trends (19).

There were several limitations to this study. First, environmental features, such as smoking status, pack-years, occupational exposure and alcohol consumption, were not available for all cases and controls included. Further, HPV assessment was not analyzed. Other features, such as bias in the selection of patients, small sample size, lack of certain clinical data and low statistical power (>0.8), were not possible to control. Also, the group of patients was not followed-up due to logistic reasons and, therefore, we could not ensure considerations concerning prognosis and therapeutic response.

In conclusion, the paramount expression of these cellular cycle biomarkers (p53 and Rb protein) in excisional biopsies may suggest that molecular lesion assessment plays a role in pre-malignant lesions. Also, p53 protein expression may be related to the early steps of carcinogenesis in OSCC, and a higher Rb protein expression was observed in malignant lesions. Therefore, larger prospective studies are warranted in order to further assess the feasibility of using the p53 and Rb proteins as putative prognostic or predictive biomarkers for OSCC.

Acknowledgements

This study was supported by the Conselho Nacional de Desenvolvimento Científico e Tecnológico (CNPQ-Brazil), and the University of Heidelberg, Germany.

References

- Jemal A, Bray F, Center M, Ferlay J, Ward E and Forman D: Global cancer statistics. *CA Cancer J Clin* 61: 69-90, 2011.
- Jemal A, Siegel R, Xu J and Ward E: Cancer statistics, 2010. *CA Cancer J Clin* 60: 277-300, 2010.
- de Mello R, Costa B, Reis R and Hespanhol V: Insights into angiogenesis in non-small cell lung cancer: molecular mechanisms, polymorphic genes, and targeted therapies. *Recent Pat Anticancer Drug Discov* 7: 118-131, 2012.
- de Mello R, Figueiredo P, Marques M, Sousa G, Carvalho T and Gervásio H: Concurrent breast stroma sarcoma and breast carcinoma: a case report. *J Med Case Reports* 4: 414, 2010.
- Osman I, Sherman E, Singh B, *et al*: Alteration of p53 pathway in squamous cell carcinoma of the head and neck: impact on treatment outcome in patients treated with larynx preservation intent. *J Clin Oncol* 20: 2980-2987, 2002.
- Mojtahedi Z, Hashemi S, Khademi B, *et al*: p53 codon 72 polymorphism association with head and neck squamous cell carcinoma. *Braz J Otorhinolaryngol* 76: 316-320, 2010.
- Sartor M, Steingrimsdottir H, Elamin F, *et al*: Role of p16/MTS1, cyclin D1 and RB in primary oral cancer and oral cancer cell lines. *Br J Cancer* 80: 79-86, 1999.
- Tanaka N, Ogi K, Odajima T, *et al*: pRb2/p130 protein expression is correlated with clinicopathologic findings in patients with oral squamous cell carcinoma. *Cancer* 92: 2117-2125, 2001.
- Bryne M, Koppang H, Lilleng R and Kjaerheim A: Malignancy grading of the deep invasive margins of oral squamous cell carcinomas has high prognostic value. *J Pathol* 166: 375-381, 1992.
- Machiels J and Schmitz S: Management and palliative chemotherapy for metastatic or recurrent squamous cell carcinoma of the head and neck. *Expert Rev Anticancer Ther* 11: 359-371, 2011.
- Massano J, Regateiro F, Januário G and Ferreira A: Oral squamous cell carcinoma: review of prognostic and predictive factors. *Oral Surg Oral Med Oral Pathol Oral Radiol Endod* 102: 67-76, 2006.
- Ko C and Citrin D: Radiotherapy for the management of locally advanced squamous cell carcinoma of the head and neck. *Oral Dis* 15: 121-132, 2009.
- Reed E: Platinum-DNA adduct, nucleotide excision repair and platinum based anti-cancer chemotherapy. *Cancer Treat Rev* 24: 331-344, 1998.
- Grem J: 5-Fluorouracil: forty-plus and still ticking. A review of its preclinical and clinical development. *Invest New Drugs* 18: 299-313, 2000.
- Feller L, Wood N, Khammissa R and Lemmer J: Human papillomavirus-mediated carcinogenesis and HPV-associated oral and oropharyngeal squamous cell carcinoma. Part 1: human papillomavirus-mediated carcinogenesis. *Head Face Med* 15: 14, 2010.
- Partridge M, Emilion G, Pateromichelakis S, A'Hern R, Phillips E and Langdon J: Allelic imbalance at chromosomal loci implicated in the pathogenesis of oral precancer, cumulative loss and its relationship with progression to cancer. *Oral Oncol* 34: 77-83, 1998.
- Nakahara Y, Shintani S, Mihara M, Kiyota A, Ueyama Y and Matsumura T: Alterations of Rb, p16(INK4A) and cyclin D1 in the tumorigenesis of oral squamous cell carcinomas. *Cancer Lett* 160: 3-8, 2000.
- Sudbø J and Reith A: Which putatively pre-malignant oral lesions become oral cancers? Clinical relevance of early targeting of high-risk individuals. *J Oral Pathol Med* 32: 63-70, 2003.
- Girod S, Pfeiffer P, Ries J and Pape H: Proliferative activity and loss of function of tumour suppressor genes as 'biomarkers' in diagnosis and prognosis of benign and preneoplastic oral lesions and oral squamous cell carcinoma. *Br J Oral Maxillofac Surg* 36: 252-260, 1998.
- de Oliveira L, Ribeiro-Silva A and Zucoloto S: Prognostic impact of p53 and p63 immunorexpression in oral squamous cell carcinoma. *J Oral Pathol Med* 36: 191-197, 2007.
- Shah N, Trivedi T, Tankshali R, *et al*: Prognostic significance of molecular markers in oral squamous cell carcinoma: a multivariate analysis. *Head Neck* 31: 1544-1556, 2009.
- Weinberger P, Merkley M, Lee J, *et al*: Use of combination proteomic analysis to demonstrate molecular similarity of head and neck squamous cell carcinoma arising from different subsites. *Arch Otolaryngol Head Neck Surg* 135: 694-703, 2009.
- Brunotto M, Zárate A, Cisonondi A, Fernández Mdel C and Noher de Halac R: Valuation of exfoliative cytology as prediction factor in oral mucosa lesions. *Med Oral Patol Oral Cir Bucal* 10: E92-E102, 2005.