

## Immunoregulatory and Effector Activities in Human Cutaneous and Mucosal Leishmaniasis: Understanding Mechanisms of Pathology

Walderez O. Dutra,<sup>1,2,4</sup> Daniela Rodrigues de Faria,<sup>1</sup> Paulo Roberto Lima Machado,<sup>3,4</sup> Luiz Henrique Guimarães,<sup>3,4</sup> Albert Schriefer,<sup>3,4</sup> Edgar Carvalho,<sup>3,4</sup> and Kenneth J. Gollob<sup>2,4,5\*</sup>

<sup>1</sup>Departamento de Morfologia, Laboratório de Biologia das Interações Celulares, Instituto de Ciências Biológicas, Universidade Federal de Minas Gerais, Belo Horizonte, MG 31270, Brazil

<sup>2</sup>Tropical Disease Research Program, Center for Infectious Disease Research, Biosciences Division, SRI International, Menlo Park, CA 94025

<sup>3</sup>Serviço de Imunologia, Hospital Universitário Professor Edgar Santos, Universidade Federal da Bahia, Salvador, BA 40110, Brazil

<sup>4</sup>Instituto Nacional de Ciência e Tecnologia, Doenças Tropicais, Belo Horizonte, MG 31270, Brazil

<sup>5</sup>Santa Casa Hospital, Graduate Program in Biomedicine and Medicine, Belo Horizonte, MG 30150, Brazil

Strategy, Management and Health Policy				
Enabling Technology, Genomics, Proteomics	Preclinical Research	Preclinical Development Toxicology, Formulation Drug Delivery, Pharmacokinetics	Clinical Development Phases I-III Regulatory, Quality, Manufacturing	Postmarketing Phase IV

**ABSTRACT** Individuals infected with *Leishmania braziliensis* may develop the relatively benign localized cutaneous (CL) form or the mucosal (ML) form of the disease, which represents a more severe and mutilating variation. Interaction between parasite and host cells, as well as the genetic background of the host, are important determinants of the immune response, which is critical in determining disease outcome. Our studies over the years have been designed to determine the immunoregulatory and effector functions that culminate in the formation of lesions in CL and ML disease and how these host response factors may be better understood for design of novel therapies and prophylaxis. By studying the immune response from CL and ML patients in both the peripheral blood and in situ, we have learned much concerning the dynamics of the host–pathogen interaction that leads to the development of CL and ML. We used multiparameter flow cytometry to study the immunoregulatory profiles of the peripheral blood leukocytes, as well as laser scanning confocal microscopy to examine in situ several aspects of the local response, including the intensity of the inflammatory infiltrate, the cellular composition, inflammatory and anti-inflammatory cytokine expression, and the expression of the effector cytotoxic molecule, granzyme A, in lesions from CL and ML patients. Moreover, the application of correlative analysis between these immunological parameters has helped shed light on disease progression in CL and ML. These findings are reviewed within the context of understanding cellular and molecular mechanisms associated with the development of pathology in these diseases through a comparative analysis of the clinical forms, CL and ML, as well as of studies derived from peripheral blood and lesions. Drug Dev Res 72:430–436, 2011. © 2011 Wiley-Liss, Inc.

**Key words:** leishmaniasis; immunoregulation; pathology; human

Grant sponsors: NIH-Tropical Medicine Research Centers Program; NIH-NIAID; Grant numbers: RO3AI066253; RO3AI066253-03; Grant sponsors: CNPq Universal; INCT-DT; FAPEMIG.

\*Correspondence to: Kenneth J. Gollob, Center for Infectious Disease Research, Tropical Disease Research Program, Biosciences Division, SRI International, 333 Ravenswood Ave. Menlo Park, CA 94025. E-mail: kenneth.gollob@sri.com

Published online in Wiley Online Library (wileyonlinelibrary.com). DOI: 10.1002/ddr.20449

## INTRODUCTION

Over the past years, our group has been studying the mechanisms that underlie the immunopathology associated with human infection by *Leishmania braziliensis*. A series of studies were performed evaluating the response of peripheral blood mononuclear cells as well as lesions from individuals with the cutaneous (CL) and the mucosal (ML) forms of human leishmaniasis, in individuals from Corte de Pedra, an endemic area localized in the interior region of Bahia, ~270 km from Salvador. We present a review of the data collected by our group over the years, which has provided important contributions toward the understanding of the dynamic immune response observed in human leishmaniasis patients with different clinical forms of the disease. These results confirmed the hypothesis that ML patients display a highly exacerbated inflammatory response, associated with the production of inflammatory cytokines and cytotoxic effector molecules, and the low expression of the receptor for IL-10, an important anti-inflammatory cytokine.

## CLINICAL EVOLUTION OF HUMAN TEGUMENTARY LEISHMANIASIS: PARASITE AND HOST FACTORS

Whereas human infection with different species of the parasite *Leishmania* leads to the establishment of different clinical diseases, it has been demonstrated that infection with the same species may also lead to the establishment of different clinical forms of leishmaniasis. Most individuals infected with the species *Leishmania braziliensis* develop a relatively mild form of the disease, the localized cutaneous (CL) clinical form, which is susceptible to treatment and confers protective immunity [Gollob et al., 2005]. However, some individuals develop a more severe and mutilating form of the disease, the mucosal (ML) clinical form. Patients with ML are often refractory to conventional antimony treatment; the clinical manifestation of the disease involves the establishment of destructive lesions that may affect the oral mucosa, nose, and oropharyngeal tract [Lessa et al., 2007]. Thus, ML presents a serious condition that can interfere significantly with patient's professional and social life and, depending on the severity, may lead to death. The reasons for the development of these different clinical forms are not completely understood and likely involve both host and parasite factors.

One possibility investigated by Schriefer et al. [2004] was that differences within the *L. braziliensis* population from Corte de Pedra were associated with the development of CL or ML. A number of parasite isolates were obtained from individuals with CL or ML; these parasites were genetically characterized.

Although all these parasites belonged to the same species, it was clearly demonstrated that genetic differences existed between them, and that these differences were correlated with the different clinical outcomes [Schriefer et al., 2004]. How the genetic differences manifested phenotypically to produce different diseases remains a puzzling question. It is possible that such genetic differences could lead to changes in parasite characteristics that would interfere with host cell-parasite interactions, in turn, influencing the host immune response. Thus, the establishment of a protective or pathogenic immune response would be related to parasite characteristics that influence the host response [Gollob et al., 2005]. Although parasite-related factors are important for the development of the disease, the mounting of an immune response also depends on other factors that must be taken into account. Recent studies have suggested that functional polymorphisms in genes that code for molecules that control the immune response are associated with the establishment of CL and ML. Of note, are the polymorphisms in genes that code for cytokines and chemokines such as IL-6, CCL-2, and IL-10 [Castellucci et al., 2006; Ramasawmy et al., 2010; Salhi et al., 2008]. Thus, the host genetic background is another factor that can influence the outcome of the infection by interfering directly with the establishment of the host's immune response.

## PERIPHERAL CELLULAR IMMUNE RESPONSES IN CUTANEOUS AND MUCOSAL LEISHMANIASIS: THE IMPORTANCE OF ESTABLISHING ACTIVE SYSTEMIC IMMUNOREGULATORY MECHANISMS

In an attempt to decipher whether there were differences in the cellular immune response that could explain the development of distinct clinical forms of leishmaniasis, a series of studies using peripheral blood mononuclear cells (PBMC) from CL and ML patients were performed. Evaluating the production of inflammatory cytokines by PBMC from CL and ML upon in vitro stimulation with soluble *Leishmania* antigens (SLA), Bacellar et al. [2002] demonstrated that while the production of IFN- $\gamma$  and TNF- $\alpha$  were higher in supernatants from cell cultures from ML as compared with CL, IL-10 levels were similar in the same cultures [Bacellar et al., 2002]. It was also demonstrated that CD4<sup>+</sup> T cells were the main source of the inflammatory cytokines in ML. Further studies by our group showed that the frequency of activated T cells were higher in the peripheral blood of ML as compared with CL patients and that there was a positive correlation between the expression of IL-10 and TNF- $\alpha$  by circulating monocytes from CL but not from ML patients [Gaze et al., 2006]. This finding

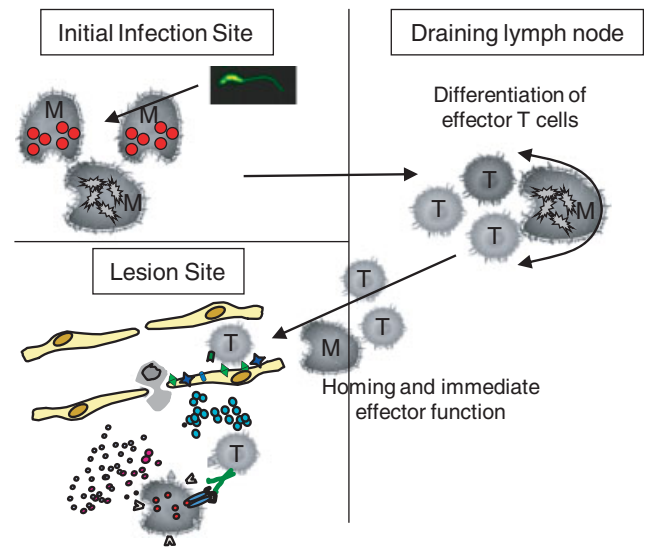
suggested that ML patients lack a co-regulation of inflammatory versus anti-inflammatory cytokine production by monocytes, which could favor the establishment of an inflammatory response in ML. Further studies demonstrated that inflammatory cytokines are directly related to lesion development, as there is a positive correlation between the frequency of IFN- $\gamma$  and TNF- $\alpha$ -producing cells and the size of the lesion in CL [Antonelli et al., 2004, 2005]. Other studies suggested that the presence of anti-inflammatory cytokines, such as IL-10, may be protective in CL. Asymptomatic individuals display lower levels of IFN- $\gamma$  production and higher levels of IL-10 production, as compared with patients with active disease [Bittar et al., 2007]. Furthermore, the same group showed that the ratio of IFN $\gamma$ /IL-10 was higher in ML as compared with CL, because of the great predominance of the inflammatory cytokine in ML [Gomes-Silva et al., 2007]. Contrary to this hypothesis, Salhi et al. [2008] showed that active lesions in CL patients were associated with high levels of IL-10 and that a single nucleotide polymorphism in the IL-10 gene that led to the high transcription of the IL-10 gene was associated with the development of CL [Salhi et al., 2008]. Based on these data, the authors suggest a pathogenic rather than protective role for IL-10 in CL. It is important to keep in mind that, even in the presence of active lesions, IL-10 production is expected, as a mechanism of control of the inflammatory reaction, which is consistent with the healing of the lesions often observed in CL patients.

To better understand the cytokine network in human leishmaniasis and the influences of cytokines on the production of one another, studies using recombinant cytokines and cytokine-blocking antibodies were performed. Anti-IL-2 monoclonal antibodies were able to decrease the production of IFN- $\gamma$  in cultures of cells from CL and ML stimulated with SLA, suggesting that this cytokine is an important factor for sustaining IFN- $\gamma$ -producing cells in culture [Carvalho et al., 2007]. However, although anti-IL-15 blocking antibodies lowered the production of IFN- $\gamma$  in cultures from CL, it did not have any effect in the production of IFN- $\gamma$  in cultures from ML [Carvalho et al., 2007]. These data suggest that the cells involved in the production of IFN- $\gamma$  in CL and ML display different phenotypic characteristics, such as the expression of cytokine receptors. In line with this thought, an intriguing data was that the addition of the modulatory cytokine IL-10 to the cultures led to the inhibition of IFN- $\gamma$  production by cells from CL, but not from ML patients [Bacellar et al., 2002]. The data obtained from the studies with PBMC suggested that patients with ML displayed a more exacerbated immune response, associated with the presence of activated T cells and

the production of inflammatory cytokines, which could influence lesion establishment and development.

### INSIGHTS INTO THE PATHOGENESIS OF HUMAN CUTANEOUS AND MUCOSAL LEISHMANIASIS: QUANTITATIVE DIFFERENCES IN SITU SET THE STAGE

The mechanisms of lesion formation involve a series of events such as cell migration, activation, and recruitment. Figure 1 summarizes some of the cellular and molecular events involved in the establishment of an inflammatory lesion. In the case of human leishmaniasis, the parasite will enter resident phagocytic cells at the site of infection, which will then become activated. Upon activation, these cells will secrete cytokines and chemokines that will activate neighboring cells such as stromal and endothelial cells; the endothelial cells will express adhesion molecules suitable for the recruitment of inflammatory cells. The phagocytic cells will also migrate to the draining lymph node carrying the parasite and its antigens. Parasite-reactive T cells present in the lymph node will



**Fig. 1.** Representation of local immune cascade focusing on host macrophages and T cells. Tissue resident and rapidly homing macrophages and monocytes containing live *Leishmania* or *Leishmania* antigen transit to the draining lymph node where they will present antigen to host T cells capable of recognizing *Leishmania* antigens. These cells will become activated and differentiate into effector cells and leave the lymph node where they are available to home to the forming lesion site. Upon arrival at the lesion site they will exert their effector functions together with activated macrophages and act to both control replication of *Leishmania* and contribute to lesion formation. Depending on a given cell's activation state and cytokine profile, it can either act to down-regulate inflammatory activities or to exacerbate these activities at the lesion site and thus the overall balance of a variety of cell types is key toward the outcome of an anti-*Leishmania* response. [Color figure can be viewed in the online issue which is available at [wileyonlinelibrary.com](http://wileyonlinelibrary.com).]

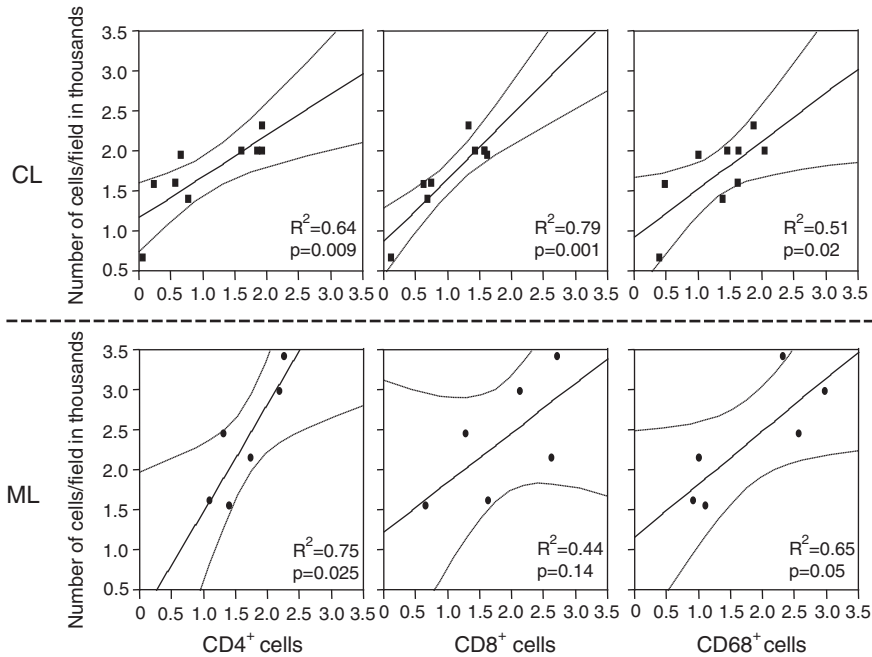
become activated upon contact with parasite-harboring phagocytic antigen presenting cells. These activated T cells will then express adhesion molecules that will address them to inflammatory sites. Activated T cells will gain the circulation and, upon contact with adhesion molecule ligands expressed by the endothelia at the inflammatory site, will adhere and respond to the chemotactic stimuli provided by the local chemokines. This response culminates with cell transmigration from the capillary into the connective tissue, where these cells will produce more cytokines and effector molecules which will potentiate the inflammatory reaction, activate other cells to kill the parasite, but also, if not controlled, mediate tissue destruction. Although the basic migration/recruitment events described are common among CL and ML lesions (and most other inflammatory lesions), certain aspects related to qualitative or quantitative differences in the expression of cytokines and effector molecules may help understand the dynamics of lesion formation/maintenance in the distinct clinical forms.

Based on the data from PBMC studies, we elaborated the hypothesis that the local immune response in ML patients was more exuberant than in CL, leading to the severe tissue destruction observed in ML. To test this hypothesis, we evaluated the intensity of the inflammatory infiltrate, the expression of inflammatory cytokines and granzyme A; we also determined the cellular sources of these molecules. We used a multiparameter approach that employed *in situ* triple-staining immunofluorescence and laser scanning confocal microscopy to analyze lesions from ML and CL. Previous studies had shown that a mixed cytokine profile, including expression of TNF- $\alpha$ , IFN- $\gamma$ , IL-10, and IL-4, was detected in CL and ML lesions using polymerase chain reaction (PCR) and immunohistochemistry techniques [Amato et al., 2003; Caceres-Dittmar et al., 1993; Melby et al., 1993, 1994; Pirmez et al., 1990, 1993]. The use of PCR, although allowing for a sensitive analysis, does not provide information as to the intensity, composition, and architecture of the inflammatory infiltrate, nor to the cellular sources of the analyzed cytokines. Using multiparameter confocal microscopy, we demonstrated that lesions from ML patients display a more intense inflammatory infiltrate than lesions from CL [Faria et al., 2005]. Furthermore, we showed that T cells were the main cell type found in the inflammatory infiltrate from CL and ML lesions. This had been previously shown by Bittencourt and Barral [1991] using conventional histology approaches and was further confirmed in this study. We also determined that the number of cells expressing IFN- $\gamma$  was higher in lesions from ML as compared with CL, as was the intensity of IFN- $\gamma$  expression on a

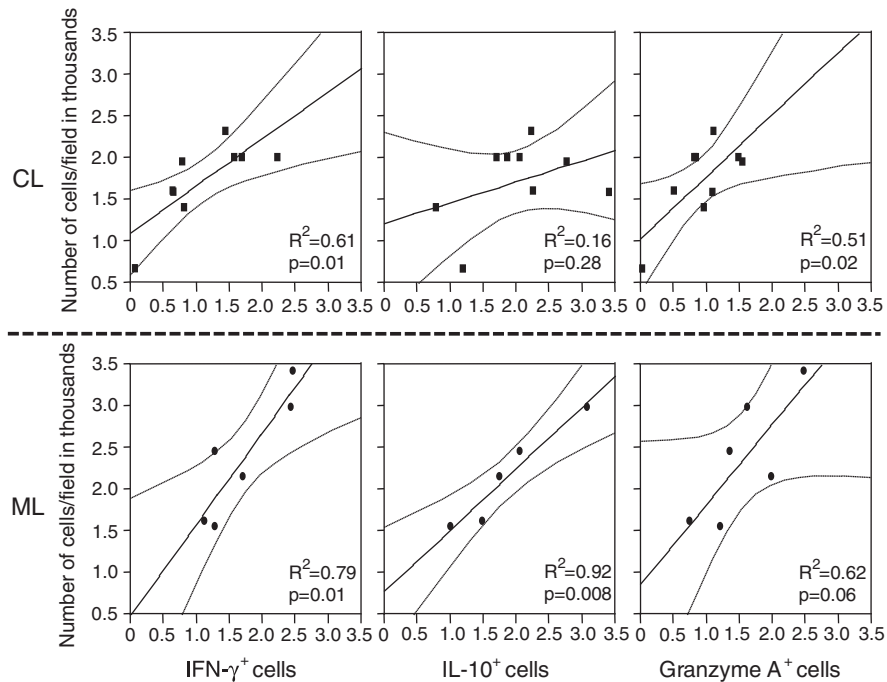
cell-per-cell basis [Faria et al., 2005]. Whereas IFN- $\gamma$  was expressed mainly by CD4<sup>+</sup> T cells in CL and ML, an interesting finding was that CD4<sup>-</sup>CD8<sup>-</sup> cells were the second main source of this cytokine in CL, corroborating previous data obtained using PBMC from CL stimulated with SLA [Bottrel et al., 2001]. The expression of TNF- $\alpha$  was similar in lesions from CL and ML.

To determine whether these parameters were directly associated with the inflammation observed in the lesions from CL and ML, we performed correlation analysis between the intensity of inflammatory infiltrate and the frequency of each cell population analyzed, as well as cytokine expression. We observed a statistically significant positive correlation between the intensity of the inflammatory infiltrate and the frequency of CD4<sup>+</sup>, CD8<sup>+</sup> T cells, and CD68<sup>+</sup> cells in CL, whereas a positive correlation was observed between the intensity of the inflammatory infiltrate and CD4<sup>+</sup> T cells and CD68<sup>+</sup> macrophages, but not CD8<sup>+</sup> T cells in ML lesions (Fig. 2). Thus, it is clear that the establishment of inflammation was correlated with the recruitment of T cells and macrophages in CL, and mainly CD4<sup>+</sup> T cells and macrophages in ML. Correlation analysis between the intensity of the inflammatory infiltrate and the expression of inflammatory cytokines showed that, in both CL and ML lesions, the more intense the inflammatory infiltrate, the higher the expression of the inflammatory cytokine IFN- $\gamma$  (Fig. 3). These data demonstrate the importance of this cytokine to lesion formation/maintenance mechanisms in human leishmaniasis.

Previous studies by Machado and colleagues have shown the presence of cytotoxic T cells in lesions from CL patients [Machado et al., 2002]. A recent study confirmed this finding, demonstrating that high levels of activated cytotoxic CD8<sup>+</sup> T cells were found in CL lesions [Da-Cruz et al., 2010]. Studying CL lesions from patients with early infection (<15 days) or late infection (>30 days), we showed that the increased intensity of the inflammatory infiltrate and lesion formation is associated with the increased number of CD8<sup>+</sup> T cells expressing granzyme A, a cytotoxic molecule [Faria et al., 2009]. It was also demonstrated that ML lesions had a higher number of granzyme A<sup>+</sup> cells than CL lesions [Faria et al., 2005]. We then further investigated the existence of a correlation between the expression of this molecule with the intensity of the inflammatory infiltrate in CL and ML. We observed that the higher the frequency of granzyme A<sup>+</sup> cells, the more intense the inflammatory infiltrate in CL and ML (Fig. 3), suggesting a role for this molecule in the mechanisms of tissue destruction in human leishmaniasis.



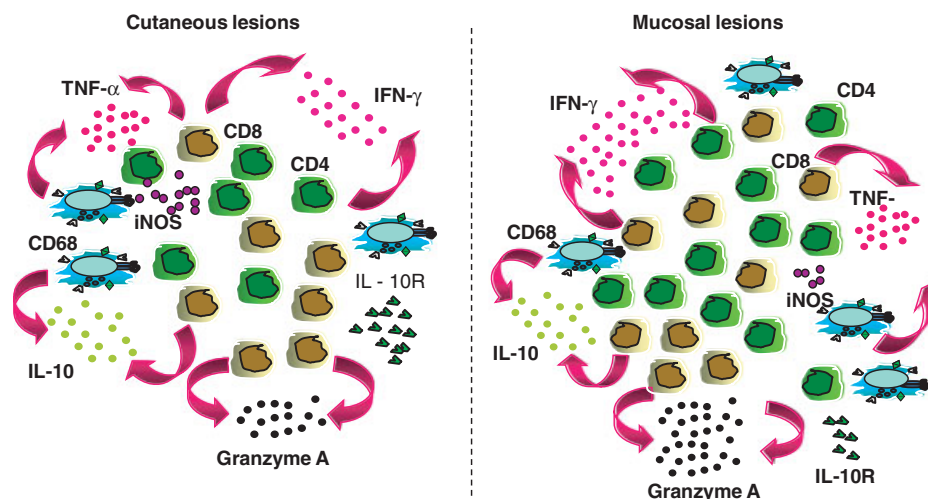
**Fig. 2.** Correlative analysis between the intensity of the inflammatory infiltrate (number of cells/field) and the number of  $CD4^+$ ,  $CD8^+$ , and  $CD68^+$  cells in lesions from cutaneous (CL) and mucosal (ML) leishmaniasis patients. Lesions were analyzed by confocal microscopy; the number of cells was determined as previously shown [Faria et al., 2005].



**Fig. 3.** Correlative analysis between the intensity of the inflammatory infiltrate (number of cells/field) and the number of  $IFN-\gamma^+$ ,  $IL-10^+$ , and granzyme  $A^+$  cells in lesions from cutaneous (CL) and mucosal (ML) leishmaniasis patients. Lesions were analyzed by confocal microscopy and the number of cells was determined as previously shown [Faria et al., 2005].

Thus, our data showed that ML lesions display a more intense inflammatory infiltrate than CL, that is directly associated with the recruitment of T cells

that express inflammatory cytokines and an effector molecule. Because the observed differences were mostly quantitative, we hypothesized that a modulatory



**Fig. 4.** Representation of the composition of lesions from cutaneous (CL) and mucosal (ML) leishmaniasis patients, showing the higher intensity of the inflammatory infiltrate in lesions from ML, presence of CD4<sup>+</sup>, CD8<sup>+</sup>, and CD68<sup>+</sup> cells in both lesions (greater in ML due to higher inflammation), increased frequency of IFN- $\gamma$  and granzyme A in ML lesions, and lower frequency of IL-10 in CL lesions. [Color figure can be viewed in the online issue which is available at [wileyonlinelibrary.com](http://wileyonlinelibrary.com).]

cytokine, specifically IL-10, would play an important role in controlling the inflammation observed in lesions from CL patients. Interestingly, our results showed that the number of cells expressing IL-10 was similar when comparing CL and ML lesions. However, the number of cells expressing IL-10 receptor was lower in ML as compared with CL lesions [Faria et al., 2005]. This finding explains the mechanism of why ML lesions display a more intense inflammatory infiltrate: the lower response to IL-10 due to the low expression of its receptor leads to the amplification of the inflammatory response. An interesting finding was that a positive correlation between the inflammatory infiltrate and number of IL-10 expressing cells was observed in ML but not CL lesions (Fig. 3). Our interpretation is that, since ML lesions display less IL-10 receptor, the production of IL-10 increases as the inflammation progresses in an attempt to compensate for the lower expression of the receptor. It is noteworthy to mention that ML lesions display few or no parasites [Bittencourt and Barral, 1991]. Thus, the inflammatory reaction, although capable of controlling the parasite, leads to tissue destruction due to the lack of proper immunological control.

### CONCLUSION

Taken together, our data showed that the pathogenesis of ML is indeed associated with an uncontrolled, self-perpetuating, inflammatory response in which inflammatory cytokines and effector molecules play an important role in mediating tissue destruction, indirect or directly. Important quantitative differences were observed when comparing the expression of

these molecules between CL and ML lesions, which explain the dynamics of lesion formation in both forms. Figure 4 summarizes the findings discussed here concerning the in situ response in CL and ML.

In a broader interpretation, these data point to the unquestionable importance of the host's immune response in the pathogenesis in CL and ML lesions. The demonstration that treatment of ML with a drug (pentoxifylline) associated with inhibition of TNF- $\alpha$  function induces cure in refractory disease [Lessa et al., 2001] or increases the cure rate in ML patients [Machado et al., 2007] argues in favor of this hypothesis. Thus, the information derived from these studies need to be taken under consideration when designing new prophylactic or therapeutic interventions, that ideally would lead to the control of the parasite but also to the subsequent modulation of the immune response to avoid excess pathology.

### ACKNOWLEDGMENTS

The authors thank all those whose contributions have allowed for a greater understanding of the pathogenesis of human leishmaniasis and apologize to others whose work was not cited here owing to format limitations. The authors have no conflict of interest.

### REFERENCES

- Amato VS, Andrade HF, Amato Neto V, Duarte MI. 2003. Short report: persistence of tumor necrosis factor- $\alpha$  in situ after lesion healing in mucosal leishmaniasis. *Am J Trop Med Hyg* 68: 527–528.
- Antonelli LR, Dutra WO, Almeida RP, Bacellar O, Gollob KJ. 2004. Antigen specific correlations of cellular immune responses in



- human leishmaniasis suggests mechanisms for immunoregulation. *Clin Exp Immunol* 136:341–348.
- Antonelli LR, Dutra WO, Almeida RP, Bacellar O, Carvalho EM, Gollob KJ. 2005. Activated inflammatory T cells correlate with lesion size in human cutaneous leishmaniasis. *Immunol Lett* 101: 226–230.
- Bacellar O, Lessa H, Schriefer A, Machado P, Ribeiro de Jesus A, Dutra WO, Gollob KJ, Carvalho EM. 2002. Up-regulation of Th1-type responses in mucosal leishmaniasis patients. *Infect Immun* 70:6734–6740.
- Bittar RC, Nogueira RS, Vieira-Goncalves R, Pinho-Ribeiro V, Mattos MS, Oliveira-Neto MP, Coutinho SG, Da-Cruz AM. 2007. T-cell responses associated with resistance to *Leishmania* infection in individuals from endemic areas for *Leishmania (Viannia) braziliensis*. *Mem Inst Oswaldo Cruz* 102:625–630.
- Bittencourt AL, Barral A. 1991. Evaluation of the histopathological classifications of American cutaneous and mucocutaneous leishmaniasis. *Mem Inst Oswaldo Cruz* 86:51–56.
- Bottrel RL, Dutra WO, Martins FA, Gontijo B, Carvalho E, Barral-Netto M, Barral A, Almeida RP, Mayrink W, Locksley R, et al. 2001. Flow cytometric determination of cellular sources and frequencies of key cytokine-producing lymphocytes directed against recombinant LACK and soluble – antigen in human cutaneous leishmaniasis. *Infect Immun* 69:3232–3239.
- Caceres-Dittmar G, Tapia FJ, Sanchez MA, Yamamura M, Uyemura K, Modlin RL, Bloom BR, Convit J. 1993. Determination of the cytokine profile in American cutaneous leishmaniasis using the polymerase chain reaction. *Clin Exp Immunol* 91:500–505.
- Carvalho LP, Passos S, Bacellar O, Lessa M, Almeida RP, Magalhaes A, Dutra WO, Gollob KJ, Machado P, de Jesus AR. 2007. Differential immune regulation of activated T cells between cutaneous and mucosal leishmaniasis as a model for pathogenesis. *Parasite Immunol* 29:251–258.
- Castellucci L, Menezes E, Oliveira J, Magalhaes A, Guimaraes LH, Lessa M, Ribeiro S, Reale J, Noronha EF, Wilson ME, et al. 2006. IL6-174 G/C promoter polymorphism influences susceptibility to mucosal but not localized cutaneous leishmaniasis in Brazil. *J Infect Dis* 194:519–527.
- Da-Cruz AM, Oliveira-Neto MP, Bertho AL, Mendes-Aguiar CO, Coutinho SG. 2010. T cells specific to leishmania and other nonrelated microbial antigens can migrate to human leishmaniasis skin lesions. *J Invest Dermatol* 130:1329–1336.
- Faria DR, Gollob KJ, Barbosa Jr J, Schriefer A, Machado PR, Lessa H, Carvalho LP, Romano-Silva MA, de Jesus AR, Carvalho EM, et al. 2005. Decreased in situ expression of interleukin-10 receptor is correlated with the exacerbated inflammatory and cytotoxic responses observed in mucosal leishmaniasis. *Infect Immun* 73:7853–7859.
- Faria DR, Souza PE, Duraes FV, Carvalho EM, Gollob KJ, Machado PR, Dutra WO. 2009. Recruitment of CD8<sup>+</sup> T cells expressing granzyme A is associated with lesion progression in human cutaneous leishmaniasis. *Parasite Immunol* 31:432–439.
- Gaze ST, Dutra WO, Lessa M, Lessa H, Guimaraes LH, Jesus AR, Carvalho LP, Machado P, Carvalho EM, Gollob KJ. 2006. Mucosal leishmaniasis patients display an activated inflammatory T-cell phenotype associated with a nonbalanced monocyte population. *Scand J Immunol* 63:70–78.
- Gollob KJ, Antonelli LR, Dutra WO. 2005. Insights into CD4<sup>+</sup> memory T cells following—infection. *Trends Parasitol* 21: 347–350.
- Gomes-Silva A, de Cassia Bittar R, Dos Santos Nogueira R, Amato VS, da Silva Mattos M, Oliveira-Neto MP, Coutinho SG, Da-Cruz AM. 2007. Can interferon-gamma and interleukin-10 balance be associated with severity of human *Leishmania (Viannia) braziliensis* infection? *Clin Exp Immunol* 149:440–444.
- Lessa HA, Machado P, Lima F, Cruz AA, Bacellar O, Guerreiro J, Carvalho EM. 2001. Successful treatment of refractory mucosal leishmaniasis with pentoxifylline plus antimony. *Am J Trop Med Hyg* 65:87–89.
- Lessa MM, Lessa HA, Castro TW, Oliveira A, Scherifer A, Machado P, Carvalho EM. 2007. Mucosal leishmaniasis: epidemiological and clinical aspects. *Braz J Otorhinolaryngol* 73: 843–847.
- Machado P, Kanitakis J, Almeida R, Chalon A, Araujo C, Carvalho EM. 2002. Evidence of in situ cytotoxicity in American cutaneous leishmaniasis. *Eur J Dermatol* 12:449–451.
- Machado PR, Lessa H, Lessa M, Guimaraes LH, Bang H, Ho JL, Carvalho EM. 2007. Oral pentoxifylline combined with pentavalent antimony: a randomized trial for mucosal leishmaniasis. *Clin Infect Dis* 44:788–793.
- Melby PC, Darnell BJ, Tryon VV. 1993. Quantitative measurement of human cytokine gene expression by polymerase chain reaction. *J Immunol Methods* 159:235–244.
- Melby PC, Andrade-Narvaez FJ, Darnell BJ, Valencia-Pacheco G, Tryon VV, Palomo-Cetina A. 1994. Increased expression of proinflammatory cytokines in chronic lesions of human cutaneous leishmaniasis. *Infect Immun* 62:837–842.
- Pirmez C, Cooper C, Paes-Oliveira M, Schubach A, Torigian VK, Modlin RL. 1990. Immunologic responsiveness in American cutaneous leishmaniasis lesions. *J Immunol* 145:3100–3104.
- Pirmez C, Yamamura M, Uyemura K, Paes-Oliveira M, Conceicao-Silva F, Modlin RL. 1993. Cytokine patterns in the pathogenesis of human leishmaniasis. *J Clin Invest* 91:1390–1395.
- Ramasawmy R, Menezes E, Magalhaes A, Oliveira J, Castellucci L, Almeida R, Rosa ME, Guimaraes LH, Lessa M, Noronha E, et al. 2010. The -2518bp promoter polymorphism at CCL2/MCP1 influences susceptibility to mucosal but not localized cutaneous leishmaniasis in Brazil. *Infect Genet Evol* 10:607–613.
- Salhi A, Rodrigues Jr V, Santoro F, Dessein H, Romano A, Castellano LR, Sertorio M, Rafati S, Chevillard C, Prata A, et al. 2008. Immunological and genetic evidence for a crucial role of IL-10 in cutaneous lesions in humans infected with *Leishmania braziliensis*. *J Immunol* 180:6139–6148.
- Schriefer A, Schriefer AL, Goes-Neto A, Guimaraes LH, Carvalho LP, Almeida RP, Machado PR, Lessa HA, de Jesus AR, Riley LW, et al. 2004. Multiclonal *Leishmania braziliensis* population structure and its clinical implication in a region of endemicity for American tegumentary leishmaniasis. *Infect Immun* 72:508–514.