

Removal of Oral Lichen Planus by CO₂ Laser

Edival Barreto de MAGALHAES-JUNIOR¹

Gilberth Tadeu ACIOLE¹

Nicole Ribeiro Silva SANTOS¹

Jean Nunes dos SANTOS²

Antonio Luiz Barbosa PINHEIRO^{1,3,4}

¹Center of Biophotonics, Dental School, UFBA - Federal University of Bahia, Salvador, BA, Brazil

²Laboratory of Surgical Pathology, Dental School, UFBA - Federal University of Bahia, Salvador, BA, Brazil

³National Institute of Optics and Photonics, Physics Institute of São Carlos,

USP - University of São Paulo, São Carlos, SP, Brazil

⁴Institute of Biomedical Engineering, UNICASTELO - Camilo Castelo Branco University,
São José dos Campos, SP, Brazil

The aim of this case report is to present a histologically diagnosed oral lichen planus excised by the CO₂ laser. Oral lichen planus is a chronic inflammatory mucocutaneous disease of unknown etiology. Different treatments have been used to manage this condition. A 46 year-old female was referred to the Laser Clinic of the Dental School of the Federal University of Bahia to excise a lesion characterized by white patches on the oral mucosa, which was causing pain and burning sensation and had not respond to treatment with triamcinolone and corticosteroids for 3 months. CO₂ laser was used to remove the lesion and the conclusive histopathological diagnosis was oral lichen planus. The patient was followed up over 1 year with no signs of lesion recurrence. The use of the CO₂ laser was found to be useful and effective to treat lichen planus.

Key Words: Oral lichen planus, CO₂ laser, laser surgery.

INTRODUCTION

Oral lichen planus is a chronic mucocutaneous disease that affects 2% of the population with a 3:1 female-to-male ratio. It is characterized by the presence of erosive lesions, bullous, papular, reticular or white patches on the oral mucosa. The mucosa and the lateral border of the tongue are the most commonly affected areas. There are reports of its association with lesions in the nails, scalp and other areas of mucosa such as on esophagus and vagina. The lesions are painless in most cases, and therefore go unnoticed (1).

Lichen planus is a disease of unknown etiology. However, it is a condition in which immune T cells are accumulated on the epithelium of the oral mucosa due to an increasing rate of differentiation in the stratified squamous epithelium, resulting in hyperkeratosis, with or without ulceration. Histologically, the diagnosis is based on the infiltration of mononuclear cells on the surface of the lamina propria, leading to the degeneration

of epithelial cells. The risk of malignant transformation remains controversial (2).

Different forms of treatment have been used to manage the lichen planus. Most treatments are conservative, with the use of topical or systemic drugs that may exacerbate the pain or burning after treatment. Conventional treatment involves the use of antifungal drugs, corticosteroids, triamcinolone, cyclosporine and metronidazole. Surgical treatment is not conventional, but high-power laser has been successfully used in the treatment of leukoplakia and premalignant lesions (3). In addition, the excimer laser has been used in biostimulation of oral lichen planus, with a photochemical effect that causes regression of the lesion (4,5).

The tissue effect of CO₂ laser is mainly produced by heat generation. This heat may result in an increase in temperature that carbonizes and vaporizes the irradiated tissues. Its action on the tissue is produced in two stages. First, the optical energy is converted into energy of vibration of the molecules that absorb radiation.

Correspondence: Prof. Dr. Antonio Luiz Barbosa Pinheiro, Centro de Biofotônica, Faculdade de Odontologia, Universidade Federal da Bahia, Avenida Araújo Pinho, 62, Canela, 40110-150 Salvador, BA, Brasil. Tel/Fax: +55-71-3283-9010. e-mail: albp@ufba.br

In a second step the energy becomes the translation, which is accompanied by an increase in temperature and consequently its chemical decomposition. Laser wounds have a small contraction of the tissue repair when compared with wounds made with a scalpel. This contraction occurs mainly in excisions, with considerable tissue loss and its goal is to approximate the edges of the wound, however, this may result in scarring. This phenomenon is due to considerable decrease or absence of myofibroblasts, which are fibroblasts with features of smooth muscle cells. In addition, hemostasis, reduced scar formation, and immediate sterilization of surgical wounds are other benefits of the CO₂ laser (6,7).

There are only 2 reports in the literature of the use of CO₂ laser for the removal of oral lichen planus in patients who received conventional therapy that was

followed by recurrence of the condition. This article reports a case of oral lichen planus removed by CO₂ laser.

CASE REPORT

A 46 year-old female was referred to the Laser Clinic of the Dental School of the Federal University of Bahia, Brazil, with white patches on the oral mucosa (Fig. 1) and complaining of pain and burning sensation. There was a conclusive histopathological diagnosis of oral lichen planus (Fig. 2) by the Laboratory of Surgical Pathology of the same institution. The lesion had been previously treated unsuccessfully with triamcinolone and corticosteroids for 3 months. The patient reported soreness and burning sensation when eating and that the lesions appeared 2 years before consultation. A detailed

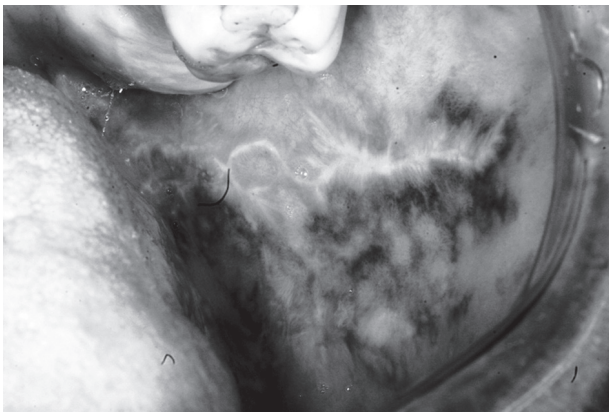


Figure 1. Preoperative clinical aspect of the lesion on the oral mucous.

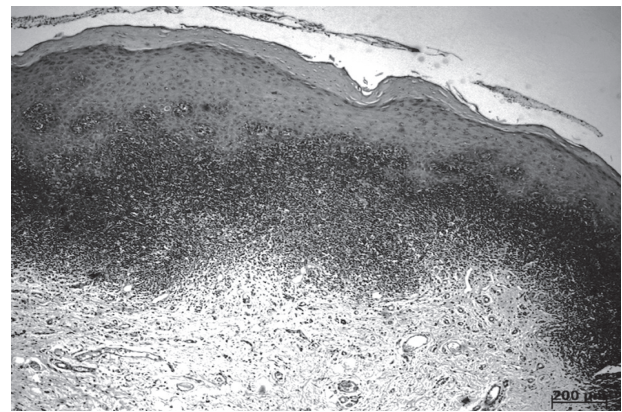


Figure 2. Histopathological aspect confirming the diagnosis of oral lichen planus.


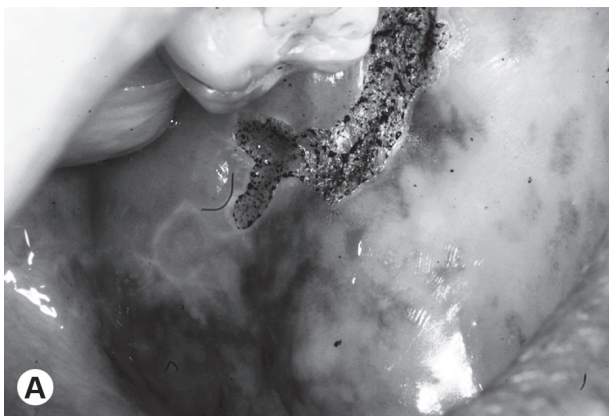


Figure 3. Immediate aspect following CO₂ laser removal. A= Aspect of the area after vaporization of the lesion (laser on focused mode); B = Aspect of the area after use of the laser on the defocused mode to improve hemostasis.

clinical interview was carried out during which the patient revealed to be under hypertensive medication (Captopril, 25 mg, once a day). No lesions were observed in the extraoral examination. A preoperative evaluation comprised complete blood count, coagulation profile, fasting glucose and urine analysis.

The surgical procedure was carried out at the Oral Maxillofacial Surgery Clinic of the same institution with a CO₂ Laser (Sharpplan 20 C; Laser Industries, Tel Aviv, Israel; $\lambda=10,600$ nm, $\phi=2$ mm, CW/RSP, power output used was 10 W). All safety measures were observed during the surgical procedures. The beam was used focused to delimit and vaporize the lesion (Fig. 3A). At the end of the surgery, the beam was used on a defocused mode to promote better hemostasis (Fig. 3B). Neither sutures nor dressings were used following the surgery. The patient received standard orientation for the postoperative period. The patient received a prescription of paracetamol (100 mg, twice a day) and nimesulide (100 mg, twice a day) during 3 days. Mouthwashes (0.12% chlorhexidine) were prescribed for the postoperative period, which was uneventful, except for mild discomfort caused by the removal of the epithelial lining. According to Van der Hem et al. (2) reepithelization occurs within 3 weeks after removal of the epithelium by the laser, and the feeling of discomfort when in contact with food or liquid disappears after that. The patient was reexamined after 1 week (Fig. 4) and 1 year after surgery with no signs of recurrence (Fig. 5).

DISCUSSION

A medium output power was used in the present




Figure 4. Clinical aspect of the area 1 week after CO₂ laser surgery.

case. The use of small output power has been shown to cause less damage and be effective on the removal of oral mucosal lesions. The less the thermal damage the better the repair. Another aspect that needs clarification is the technique used for removal of the lesion. The choice for vaporization was due to the fact that the lesion had been biopsied before.

The most interesting features of the CO₂ laser surgery are local hemostasis, cauterization of nerve endings and sealing of lymphatic vessels. In addition, the very high temperatures generated by the laser beam on the tissue sterilizes the wound surface, reduces the risk of postsurgical infection and avoids the use of antibiotic therapy. We prescribed no antibiotic to any of the patients and none showed signs of local infection on follow up time. We observed that no patient complained of pain or showed signs of infection on the post-operative period. The cauterization of the nerve endings is important as it causes the formation of thermal neuromas at the ending of the nerve causing less pain after surgery and reducing

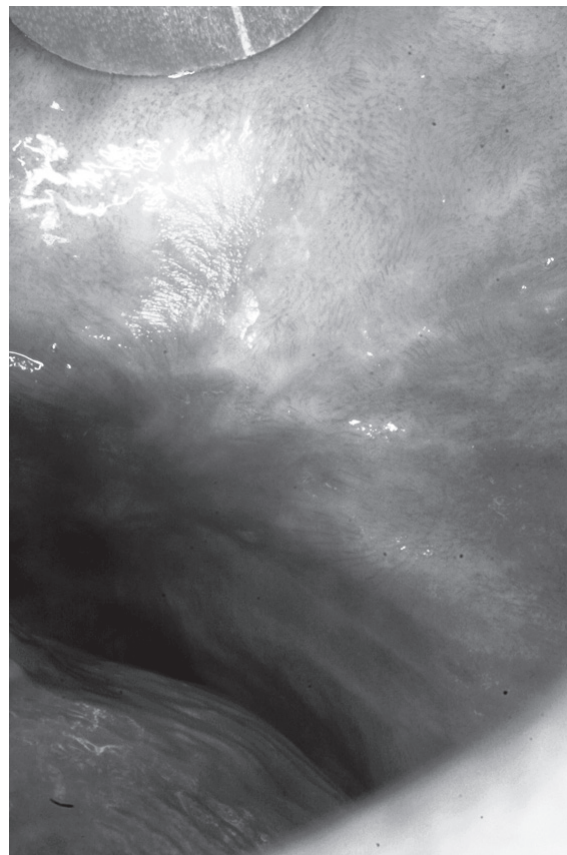


Figure 5. Clinical aspect of the area 1 year after CO₂ laser surgery.

the use of painkillers. Additionally, scar formation is minimized due to the sparse presence of myofibroblasts. This late feature is very important on the treatment of oral lesions especially on areas in which scar tissue may cause impairment of the function. It has been shown that the amount of myofibroblasts on CO₂ laser wound is 3 times less than that the found on scalpel wounds. In these procedures nor sutures nor dressings are used and the healing occurs by second intention. The use laser surgery has increased largely over the last 10 years. However, the cost of the equipment and need for qualification on surgical specialties have limited the access of dentists to its benefits. The correct indication of this surgical technique is both cost effective and reliable on the treatment of oral lesions, including premalignant ones. The use of CO₂ laser does not reduce the risk of relapses of the lesion, but it is an easy technique to use and results on both fast surgical procedure and silent postoperative period. Furthermore, it may be safely used on the dental practice (7).

In this article, we presented a case that relapsed after conventional therapy. It is known that this lesion may affect any region of the oral cavity, being the oral mucosa, tongue and gingiva the most commonly affected areas. Lesions on the palate are less frequent (7-9), occurring mainly in adults and being rarely found in children (1). A study of 200 cases showed a strong predominance in females aged between 40 and 70 years (8). In the present case, the patient had a large lesion extending from near the maxillary second molar to the lip commissure. Histologically, the case fulfilled the morphological criteria for oral lichen planus as previously reported (7-10).

The option for surgery was due to the lesion extension and the fact that it was impairing the patient's working activities. The literature presents surgical and nonsurgical treatments, depending on lesion type and extension and the patient's systemic condition (10-14). Each laser has a specific wavelength. Due to its wavelength, the CO₂ laser has very strong affinity for soft tissues because of their high fluid contents, and it is an optimal tool for removing superficial skin and mucosal lesions (14-17).

Loh (6) used CO₂ laser in 10 patients for removing tumors, showing that lichen planus did not reappear in areas hit by the laser. In the present case study, the follow up of 1 year showed no recurrence and disappearance of the burning sensation and pain. Van der Hem et al. (2) used CO₂ laser in 21 patients after treatment with

of steroids. Also, prior to surgery, those patients had indication of painful burn sensation. Laser treatment removed the lesion leaving a safety margin of 2 mm beyond the lesion and follow up indicated no more pain.

It is concluded that the use of the CO₂ laser is useful and effective in the treatment of oral lichen planus.

RESUMO

O objetivo deste relato de caso é apresentar a remoção cirúrgica com o laser de CO₂ de um líquen plano diagnosticado histologicamente. O líquen plano da cavidade oral é uma doença muco-cutânea crônica de etiologia desconhecida. Tratamentos diferentes têm sido usados para sua resolução. Uma paciente do sexo feminino de 46 anos de idade foi encaminhada para a Clínica de Laser da Faculdade de Odontologia da Universidade Federal da Bahia para a remoção de uma lesão na boca caracterizada pela presença de manchas brancas que estava causando dor e ardimento não havia respondido a tratamento com triamcinolone e corticoides durante 3 meses. O laser de CO₂ foi utilizado para remover a lesão e o diagnóstico histopatológico conclusivo foi o de líquen plano de cavidade oral. A paciente foi acompanhada durante 1 ano sem sinal de recorrência da lesão. O uso do laser de CO₂ foi considerado útil e efetivo no tratamento do líquen plano.

REFERENCES

1. Carbone M, Goss E, Carozzo M, Castellano S, Conrontto D, Broncoletti R, et al. Systemic and topical corticosteroid treatment of oral lichen planus: a comparative study with long term follow-up. *J Oral Pathology Med* 2003;32:323-329.
2. Van der hem PS, Egges M, Van der wal JE, Roodenburg JLN. CO₂ laser evaporation of oral lichen planus. *Int J Oral Maxillofac Surg* 2008;37:630-633.
3. Van der hem PS, Nauta JM, Van der wal JE, Roodenburg JLN. The results of CO₂ laser surgery in patients with oral leukoplakia: a 25 year follow up. *Oral Oncol* 2005;41:287-306.
4. Trehan M, Taylor C. Low dose Excimer 308 nm Laser for the treatment of oral lichen planus. *Arch Dermatol* 2004;140:415-430.
5. Kolnner K, Wimmershoff M, Landtaler M. Treatment of oral lichen planus with the 308 nm UVB Excimer Laser - early preliminary results in eight patients. *Lasers Surg Med* 2003;33:158-160.
6. Loh HS. A clinical investigation of the management of oral lichen planus with CO₂ laser surgery. *J Clin Laser Med Surg* 1992;10:445-449.
7. Pinheiro ALB, Cavalcanti das Neves J, Lisboa de Castro JF, Lima Verde Santos JZ, da Fonseca Ribeiro de Sena KX, Brugnera A Jr, et al. Comparison of the effects of the CO₂ laser and chlorohexidine on the decontamination of infected cutaneous wounds: a histologic study in rats. *J Clin Laser Med Surg* 2002; 20:123-127.
8. Dissemond J. Oral lichen planus: an overview. *J Dermatol Treat* 2004;15:136-140.
9. Huber MA. Oral lichen planus. *Quintessence Int* 2004;35:731-752.
10. Dorta RG, Costa CG, Oliveira DT. Medical management in patients with cutaneous and oral lichen planus *Rev Fac Odontol*

- Bauru 2000;8:23-28.
11. Mollaoglu N. Oral lichen planus: a review. *Br J Oral Maxillofac Surg* 2000;38:370-377.
 12. Esquivel-Pedraza L. Treatment of oral lichen planus with topical pimecrolimus 1% cream. *Br J Dermatol* 2004;150:771-773.
 13. Santos NRS, Aciole GTS, Marchionni AM, Soares LG, dos Santos JN, Pinheiro ALB. A feasible procedure in dental practice: the treatment of oral dysplastic hyperkeratotic lesions of the oral cavity with the CO laser. *Photomed Laser Surg* 2010;Suppl 2:S121-S126.
 14. Wang X, Ishizaki NT, Matsumoto K. Healing process of skin after CO₂ laser ablation at low irradiance: a comparison of continuous-wave and pulsed mode. *Photomed Laser Surg* 2005;23:20-26.
 15. Chandu A, Smith ACH. The use of CO₂ laser in the treatment of oral white patches: outcomes and factors affecting recurrence. *J Oral Maxillofac Surg* 2005;34:396-400.
 16. Meltzer C. Surgical management of oral and mucosal dysplasias: the case for laser excision. *J Oral Maxillofac Surg* 2007;65:293-295.
 17. Grbavac RAO, Veeck EB, Bernard JP, Ramalho LM, Pinheiro AL. Effects of laser therapy in CO₂ laser wounds in rats. *Photomed Laser Surg* 2006;24:389-396.

Received July 19, 2011

Accepted October 1, 2011